Retardation of Epithelial Migration in Monkeys Using a Carbon Dioxide Laser: An Animal Study

Jeffrey A. Rossmann, Michael J. McQuade,† and Denise E. Turunen‡*

OBTAINING A CONNECTIVE TISSUE ATTACHMENT to the root surface following a mucoperiosteal flap surgery has been a goal of periodontal therapy for a long time. The objective of this study was to examine whether controlled de-epithelialization with the CO_2 laser would retard the apical migration of the epithelium and thereby increase the amount of connective tissue attachment. Elastics were placed on the maxillary premolars and incisors of 7 cynomolgous monkeys to create periodontal defects. Open flap debridement was performed on each side. On the experimental side, the oral epithelium was removed by CO_2 laser irradiation. This report describes the 3 specimens at 7, 14, and 28 days respectively. On the control side sulcular epithelium was seen at 14 days. Sulcular epithelium was first seen on the test side at 28 days. For all specimens over 7 days, there was a trend to less epithelium and more connective tissue attachment on the experimental side than on the control side. However, no statistical analysis was possible on this histologic study. The CO_2 laser may be a useful tool to retard epithelium and thereby enhance new connective tissue attachment. *J Periodontol 1992; 63:902–907.*

Key Words: Surgical flaps; connective tissue attachment; epithelium.

Successful treatment of intrabony pockets to obtain new attachment continues to represent a serious therapeutic challenge in periodontics. Epithelial proliferation apically, along the root surface, has been shown to interfere with the establishment of a new connective tissue attachment.[1] The presence of inflammation has also been shown to stimulate epithelial migration in an apical direction.[2] Both the degree of inflammation and the "race" between connective tissue maturation (coronally) and downgrowth of epithelium appear to be important factors influencing development of a new attachment of the dentogingival unit following surgical intervention.

Historically, a number of techniques have been tried to retard epithelial downgrowth. Goldman's technique eliminated the coronal portion of the periodontal pocket by gingivectomy in conjunction with subgingival curettage.[3] Prichard employed a technique in treating intrabony defects (3-walled osseous defects) that left the interproximal areas exposed to heal by secondary intention in an attempt to keep the epithelium away from the defect.[4] Shapiro's technique for obtaining new attachment stressed the importance of removing marginal epithelium in the initial incision (inverse bevel) such that the epithelial margin was kept away from the healing defect.[5]

Other techniques for retarding epithelial migration have since been described. Ellegaard and co-workers used free gingival grafts as barriers.[6,7] Their results confirmed observations by Caffesse[8] that the traditional full thickness flap results in epithelium that is well-preserved, and placement of this flap adjacent to the treated area facilitates the migration of epithelium into the intrabony defect.[8] Nyman et al. used millipore filters to exclude epithelium and gingival connective tissue from healing surgical sites in monkeys[9] and man.[10] Bone and connective tissue attachment were regenerated, and it is postulated that the filter provides a selective advantage to periodontal ligament cells. New attachment was demonstrated on previously diseased surfaces when the millipore filters were used in conjunction with complete soft tissue coverage of the entire root.[11] More recently, the use of a expanded polytetrafluoride (eEPTF)[§] membrane for epithelial exclusion has become common practice.

The aim of the present study was to see if the use of a carbon dioxide (CO_2) laser to de-epithelialize a flap would or could act as an epithelial exclusion technique.

The most fundamental property of laser light which distinguishes it from the other sources is that it is far more coherent (individual waves are "in phase" with one another). Lasers in current use fall between infrared and ul-

*Postdoctoral Periodontics, University of Texas Health Science Center, Houston, TX.
†Postdoctoral Periodontics, Baylor College of Dentistry, Dallas, TX.
‡Department of Periodontics.

§Gore-Tex, W.L. Gore and Associates, Flagstaff, AZ.

traviolet on the electromagnetic spectrum and the specific type is defined by the wavelength of radiation emitted. The most commonly utilized types in medicine and dentistry are the carbon dioxide (CO_2) laser (wavelength 10,600 nm); the neodymium-yttrium-aluminum-garnet (Nd:YAG) laser (wave length 1,060 nm); the various ultraviolet wavelengths such as the excimer (excited dimer); and the argon laser with a wavelength of 488 to 516 nm.

The CO_2 laser is very versatile due to its ability to excise and coagulate soft tissues. This is because the beam is rapidly absorbed by water in the most superficial tissues with virtually no heat conductivity to lower layers. The Nd:YAG and the argon, on the other hand, are more penetrating lasers with the energy absorbed by deeper and more pigmented tissues. This means that the CO_2 laser has the potential for de-epithelialization while the Nd:YAG laser is generally not considered useful for this purpose. The depth of the wound produced by any laser is directly proportional to the power output, the duration of exposure, and the spot diameter of the beam.

The laser was developed by Maimon in 1960[12] and was first applied in vivo to human teeth in 1965.[13] The effects of the CO_2 laser on dental hard tissues have been studied quite extensively,[14-17] however, histologic reports of its use as an adjunct to soft tissue dental surgery are quite limited. Goultschin et al.[18] compared hard and soft tissue healing in the beagle dog model following a gingivectomy performed with a CO_2 laser to that performed with a conventional knife. Crater-like defects were observed in the cementum on the laser-treated specimens where the beam had touched the tooth. Because of the excisional type of surgical procedure, the histologic results did not demonstrate any substantial advantage of the laser over the conventional gingivectomy. Also since the intraoral handpiece had not yet been invented, the investigators experienced difficulty in controlling the laser handpiece.

Because of the very precise depths to which the laser can "cut," the purpose of this study was to determine if it is possible that the CO_2 laser could de-epithelialize the periodontal flap and delay epithelial downgrowth and hence facilitate regenerative efforts.

MATERIALS AND METHODS

In conducting the research described in this paper, the investigators adhered to the "Guide for Laboratory Animal Facilities and Care," as promulgated by the National Research Council.

For this preliminary report, 3 cynomolgus monkeys (*Macaca irus*) were used. The model followed for experimentally induced periodontitis was that established by Caton and co-workers.[19,20] Orthodontic elastics were doubled and placed at the gingival margins around the maxillary central incisors and maxillary premolars bilaterally. The elastics were changed every 2 weeks and the monkeys were fed a standard diet of Purina Monkey Chow supplemented with fresh fruit. The monkeys were maintained on this regimen until vertical bony defects were obvious by radiographic evaluation. All animals then underwent open flap curettage procedures on both sides of the maxillary arch. The experimental side was randomly determined by a coin toss.

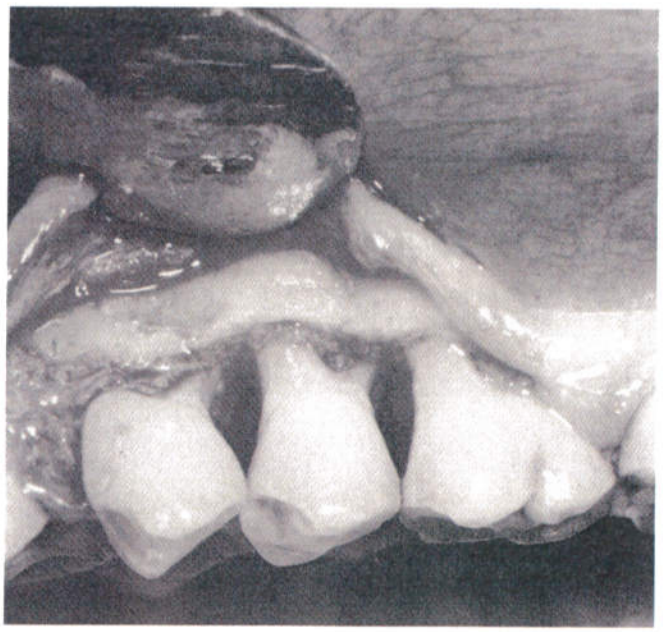

Figure 1A. Raised mucoperiosteal flap. Soft tissue was curetted from defects and roots lightly planed.

Both sides were treated simultaneously using an inverse bevel incision 1.0 mm below the free gingival margin in an effort to remove the crevicular epithelium. Full thickness mucoperiosteal flaps were then reflected on the facial and palatal aspects of the intrabony defects. The sites were degranulated with curets and the root surfaces were lightly planned (Fig. 1A). Notches were made in the root surface at the bottom of the defects with a small Wedelstadt chisel with cemento-enamel junction (CEJ) serving as a fixed reference point. The areas were irrigated with sterile saline.

On the control side, the tissue flaps were carefully adapted to the teeth and sutured with 4-0 silk suture to obtain primary coverage of the intrabony defects. On the experimental side, the outer surface of the flaps was irradiated with the CO_2 laser.[‖] The incident laser beam was held perpendicular to the tissue surface and was focused to a 2 mm circular spot using a 400 mm focal length lens. The tissue surfaces were exposed to impacts of 0.5 seconds duration at 10 watts.[21,22] (Fig. 1B)

The impacts were adjoining and slightly overlapping to ensure complete irradiation of the flap overlying the intrabony defects. The carbonized layer was then removed by wiping with a moist gauze. The de-epithelialized tissue flaps were then carefully adapted to the teeth and sutured over the intrabony defects, identical to the control side (Fig. 1C). Following surgery, each monkey received a rubber cup prophylaxis 3 times a week.

‖Model 400, Coherent Medical Products, Palo Alto, CA.

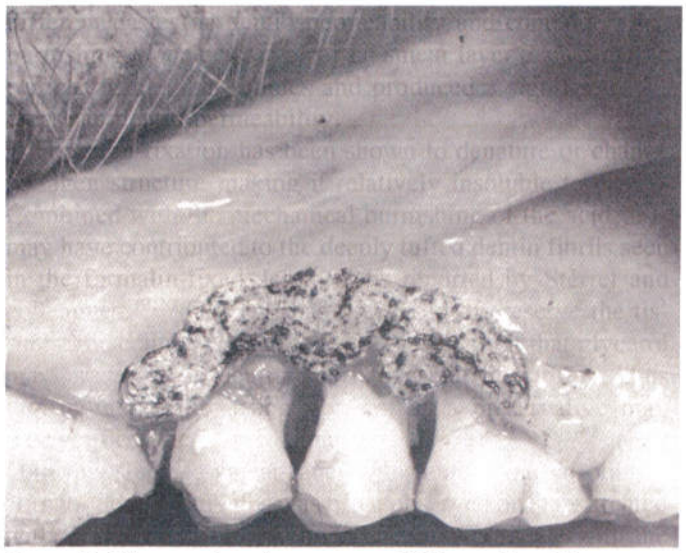

Figure 1B. Tissue surface after exposure of 0.5 seconds at 10 watts.

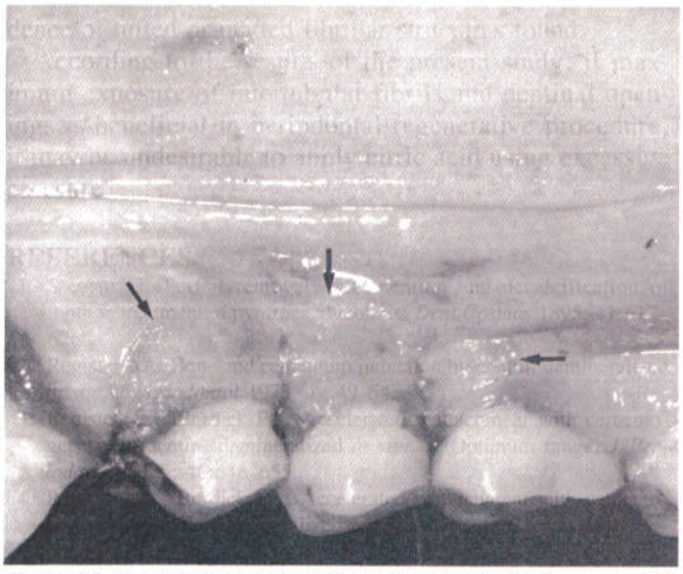

Figure 1C. De-epithelialized tissue flaps adapted to the teeth and sutured over the intrabony defects.

The animals reported in this paper were sacrificed at 7, 14, and 28 days respectively following surgery and the tissues were prepared for histologic examination. Ten mesial to distal representative sections were taken from each animal and the average of these 10 measurements was taken (Table 1). One animal and its 10 sections represented each time period. The sections were measured to the nearest 0.10 mm with a calibrated stereometric microscopic system with the CEJ serving as a fixed reference point. Distances between the CEJ and various landmarks of the periodontal tissues were measured using a calibrated disc in the eyepiece of a light microscope. These measurements included:

1. The distance in mm from the CEJ to the notch in the tooth surface depicting the most apical point of the intrabony defect at surgery.

Table 1. Histometric Measurements of Healing Defects

Days	Control			Experimental		
	CEJ-AN	CEJ-JE	CT	CEJ-AN	CEJ-JE	CT
7	3.16	*	*	3.09	*	*
14	3.00	2.08	0.92	3.02	*	1.80
28	2.61	1.68	1.10	3.35	1.72	1.62

Measurements are in mm and represent averages of multiple histologic sections on the same specimen. These are mean values.
AN = apical notch.
JE = junctional epithelium.
CT = connective tissue.
*No epithelial downgrowth was present.

2. The distance in mm from the CEJ to the apical extent of the healed junctional epithelium.

3. The distance in mm from the CEJ to the crest of the alveolar bone. The extent of the epithelial migration along the tooth surface from the CEJ was then computed and the two sides were compared (Table 1).

RESULTS

7-Day Specimens

The control sides showed minimal inflammation; no epithelium was seen and the collagen appeared to be viable. Fibroblastic activity was observed apical to the level of the notch delineating the base of the defect. A fibrinous clot was present at the base of the defects and below this the tissues were edematous. Small fragments of necrotic bone were present in the connective tissue adjacent to the notches.

On the experimental sides, the inflammation was mild to moderate and no epithelium was present. The tissue was edematous and an eosinophilic coagulum was present. Superficial necrosis was observed where the inflammation was most intense. Marked fibroblastic activity was present. Localized areas of osteoclastic activity approximated small bone spicules.

14-Day Specimens

The control sides were slightly inflamed. Keratinized epithelium extended apically into the sulcus. The amount of epithelial downgrowth was less than 25%, was heavily keratinized and had a well-established spinous layer. Few fibroblasts were present but there was early osteoblastic activity (Fig. 2A). Histrometrically there was a distance of 2.08 mm from the CEJ to the base of the junctional epithelium and 0.92 mm of connective tissue attachment.

The experimental sides were also slightly inflamed with with no epithelium lining the sulcular aspect of the flap nor any indication of junctional epithelium. In the underlying connective tissue there was intense fibroblastic activity. A fibrin clot was observed at the base of the defects. Fragments of necrotic bone were seen throughout the stroma at the level of the notch and apical to the defects (Fig 2B). Nearly twice as much connective tissue attachment was

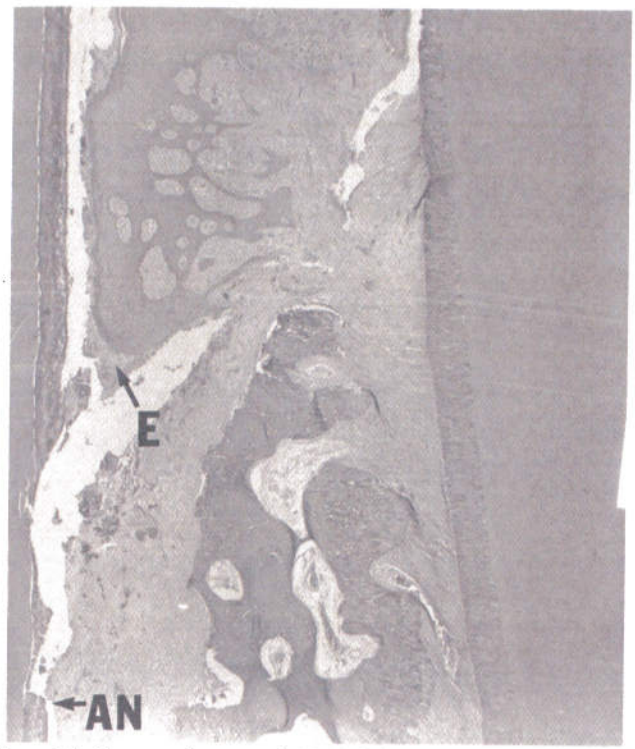

Figure 2A. Fourteen-day control. Epithelial downgrowth into sulcus (E) and early osteoblastic activity (AN = apical notch) (H & E stain, original magnification × 20).

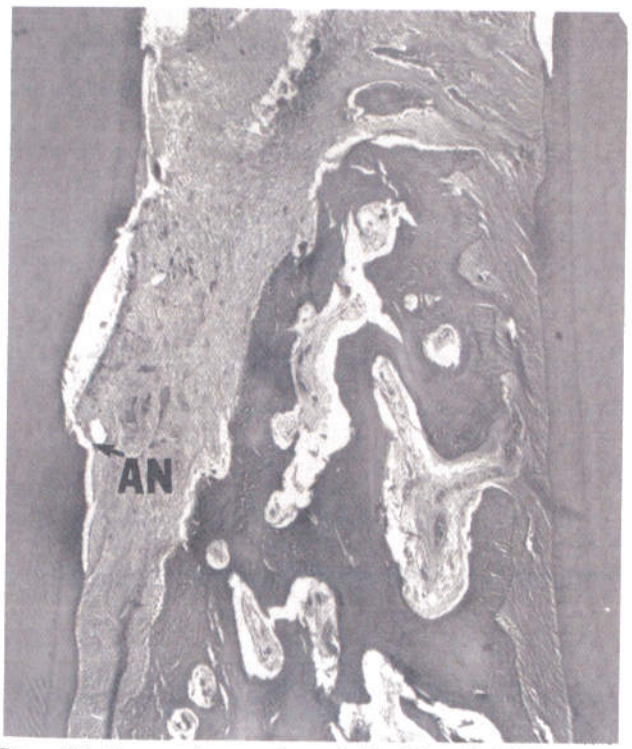

Figure 2B. Fourteen-day experimental side. No epithelial downgrowth. Fragments of dead bone are seen in the defect and adjacent stroma (H & E stain; original magnification × 20).

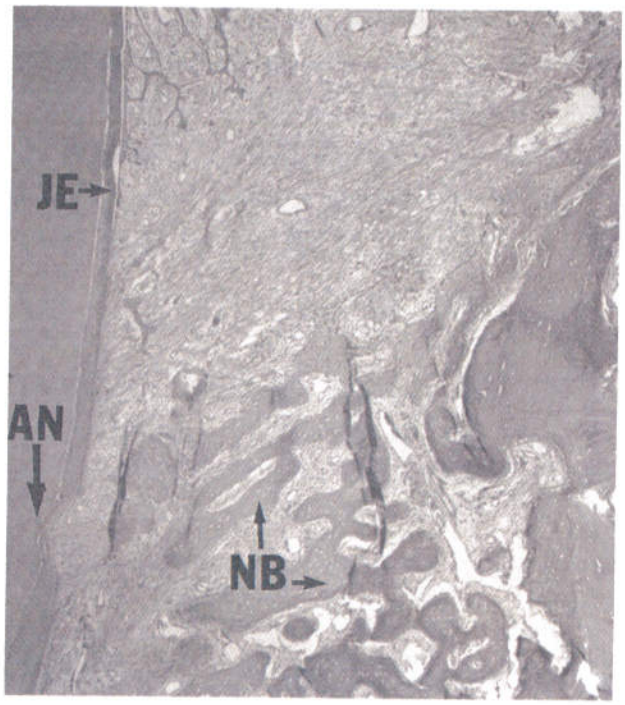

Figure 3A. Twenty-eight day control. Junctional epithelium extends to 60% of defect (H & E stain; original magnification × 20).

found in these sections compared to the control (1.80 mm vs. 0.92 mm).

28-Day Specimens

The control sides were slightly inflamed. The epithelium was several layers thick and extended from 55% to 65% of the defect. Small amounts of connective tissue and cementum were noted but there was only minimal new bone formation in the deeper portion of the defects (Fig. 3A). The average distance from the CEJ to the junctional epithelium base was less than that seen at 14 days (2.08 mm vs. 1.68 mm).

The experimental sides were also inflamed. Epithelial downgrowth was seen for the first time as a thin layer extending halfway to the base of the defect. New connective tissue attachment was observed. New bone formation extended from the notch to the level of epithelial downgrowth (Fig 3B). Much more connective tissue attachment was seen than in the control (1.62 mm vs. 1.10 mm).

DISCUSSION

The purpose of this pilot research was to determine whether or not a CO_2 laser could be used to effectively retard the downgrowth of epithelium into a treated periodontal defect. Based on the data collected, our observations were that the CO_2 laser did, in fact, alter the course of healing.

In all 3 early cases, irradiation of the experimental side resulted in delayed epithelial downgrowth along the root surface. Comparison of the results at 7 and 14 days suggests

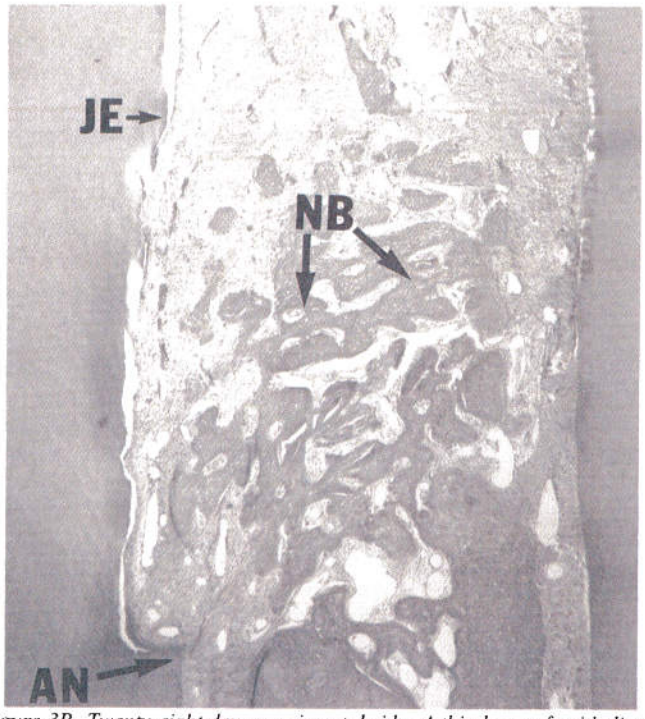

Figure 3B. Twenty-eight day experimental side. A thin layer of epithelium extends to half of defect. There is a suggestion of connective tissue attachment and new bone (NB) growth (H & E stain; original magnification × 20).

that epithelialization was retarded by at least 7 days when compared to the control, but epithelial migration was roughly equal by 28 days. The healing of the connective tissue on the irradiated side not seem to be retarded. In this preliminary report, no hypothesis testing of the data was done. The thrust of this paper is therefore to present histologic observations in the de-epithelialization using a carbon dioxide laser and quantity differences in terms of millimeters.

In light of the significant interest in lasers today, one might speculate on the effect that an Nd:YAG or the argon laser would have versus the carbon dioxide laser. The carbon dioxide laser has a very shallow depth of penetration and a shallower depth of thermal coagulation than the Nd:YAG or the argon. The latter two mentioned laser beams tend to pass through epithelium and be absorbed by the deeper pigmented tissues. Therefore the carbon dioxide laser is more apt to de-epithelialize only and not harm underlying connective tissue. The carbon dioxide laser was thus chosen for this experiment.

The CO_2 laser has been used in otolaryngology and gynecology for almost two decades and has become a valuable tool for controlled tissue devitalization, vascular coagulation, excisional surgery, and endoscopic and microsurgery.[23] There has been much less experimentation to histologically evaluate the laser as a surgical adjunct in dentistry.

Within the limitations of this study, it appears that de-epithelialization by the CO_2 surgical laser can retard the apical downgrowth of epithelium during flap surgery in monkeys. Although in some instances root resorption has been reported as a complication of treatment with other epithelial exclusion techniques,[24,25] no root resorption was observed in this study. Additionally, the CO_2 laser is less technically demanding and more time efficient than other currently known methods of epithelial retardation, possibly making it a desirable adjunct to periodontal regenerative procedures. Future quantitative histologic studies are needed to evaluate the effect of combined laser/membrane exclusion regenerative techniques.

Acknowledgment

The authors wish to thank Dr. Brent Koudelka for his assistance in reviewing the histologic sections and Dr. Robert Prior for his help in manuscript preparation.

REFERENCES

1. Skillen WG, Lundquist GR. An experimental study of periodontal membrane reattachment in healthy and pathologic tissues. *Dent Cosmos* 1937;24:175–185.
2. Ramfjord S. Experimental periodontal reattachment in Rhesus monkeys. *J Periodontol* 1951;22:67–76.
3. Goldman HM. A rationale for the treatment of the intrabony pocket, one method of treatment-subgingival curettage. *J Periodontol* 1949;20:89–91.
4. Prichard J. A technique for treating intrabony pockets based on alveolar process morphology. *Dent Clin N Am* 1960(Mar);85–105.
5. Shapiro M. A reattachment operation. *Dent Clin N Am* 1960(Mar);5–25.
6. Ellegaard B, Karring T, Löe H. New periodontal attachment procedure based on retardation of epithelial migration. *J Clin Periodontol* 1974;1:75–88.
7. Ellegaard B, Karring T, Löe H. Retardation of epithelial migration in new attachment attempts in intrabony defects in monkeys. *J Clin Periodontol* 1976;3:23–37.
8. Caffesse RG, Ramfjord SP, Nasjleti CE. Reverse bevel periodontal flaps in monkeys. *J Periodontol* 1968;39:219–235.
9. Nyman S, Gottlow J, Karring T, Lindhe J. The regenerative potential of the periodontal ligament. An experimental study in the monkey. *J Clin Periodontol* 1982;9:257–265.
10. Nyman S, Lindhe J, Karring T, Rylander H. New attachment following surgical treatment of human periodontal disease. *J Clin Periodontol* 1982;9:290–296.
11. Gottlow J, Nyman S, Karring T, Lindhe J. New attachment formation as the result of controlled tissue regeneration. *J Clin Periodontol* 1984;11:494–503.
12. Maimon TH. Stimulated optical radiation in ruby. *Nature* 1960;187:493.
13. Goldman L, Gray JA, Goldman J, Goldman B, Meyer R. Effect of laser impacts on teeth. *JAMA* 1965;70:601–606.
14. Kantola S. Laser induced effects on tooth structure; VII. X-ray diffraction study of dentin exposed to carbon dioxide laser *Acta Odontol Scand* 1973;31:381–386.
15. Melcer J, Chaumette M-T, Melcer F. Treatment of dental decay by CO_2 laser beam-Preliminary results. *Lasers Surg Med* 1984;4:311–321.
16. Melcer J, Chaumette M-T, Melcer F. Preliminary report on the effect of the CO_2 laser beam on the dental pulp of *Macaca Mulatta* primate. *J Endodont* 1985;11:1–5.
17. Melcer J, Chaumette M-T Melcer F. Dental pulp exposed to the CO_2 laser beam. *Lasers Surg Med* 1987;7:347–352.
18. Goultschin J, Gazit D, Bichacho N, Bab I. Changes in teeth and

gingiva of dogs following laser surgery: A block surface light microscope study. *Lasers Surg Med* 1988;8:402–408.

19. Caton HG, Zander HA. Primate model for testing periodontal treatment procedures: I. Histological investigation of localized periodontal pockets produced by orthodontic elastics. *J Periodontol* 1975;46:71–77.
20. Caton JG, Kowalski CJ. Primate model for testing periodontal procedures: II. Production of contralaterally similar lesions. *J Periodontol* 1976;47:506–510.
21. Adrian JC. Effects of carbon dioxide laser radiation on oral soft tissues: An initial report. *Milit Med* 1979;144:83–89.
22. Rossmann J, Gottlieb S, Koudelka BM, McQuade MJ. Effects of carbon dioxide laser irradiation on gingiva. *J Periodontol* 1987;58:423–425.
23. Simpson GT, Polyanyi T. History of the carbon dioxide laser in otolaryngologic surgery. *Otolaryngol Clin North Am* 1983;16:739–752.
24. Lindhe J, Nyman S, Karring T. Connective tissue attachment as related to presence or absence of alveolar bone. *J Clin Periodontol* 1984;11:33–40.
25. Morris ML, Thompson RA. Healing of human periodontal tissue following surgical detachment. *Periodontics* 1963;1:189–195.

Send reprint requests to Dr. Michael J. McQuade, Director, Postgraduate Periodontics, Baylor College of Dentistry, 3302 Gaston Ave., Dallas TX 75246.

Accepted for publication May 15, 1992.