

Conventional Versus CO₂ Laser-Assisted Treatment of Peri-implant Defects with the Concomitant Use of Pure-Phase β-Tricalcium Phosphate: A 5-year Clinical Report

Herbert Deppe, Prof Dr Med Dent¹/Hans-Henning Horch, Prof Dr Med Dr Med Dent²/
Andreas Neff, PD Dr Med Dr Med Dent²

Purpose: Recently, histologic studies in the beagle dog model demonstrated that CO₂ laser-assisted implant decontamination can result in reosseointegration. Consequently, the purpose of this study was to assess the efficacy of CO₂ laser-assisted therapy as compared with conventional therapy, with the concomitant use of β-tricalcium phosphate, in humans. **Materials and Methods:** The study included 32 patients with 73 ailing implants. In the laser group, 22 implants were treated with soft tissue resection following laser decontamination; whereas in 17 implants, bone augmentation was performed. In the control group, soft tissue resection after conventional decontamination was performed in 19 implants, augmentation in 15 implants. Results were evaluated 4 months after surgery and in May 2004. **Results:** Four months after therapy, there were no significant differences in distance from implant shoulder to the first bone contact (ie, DIB values) between implants undergoing laser decontamination and soft tissue resection and implants treated with conventional decontamination followed by soft tissue resection. At the end of the study, there was a statistically significant difference between these 2 groups. Four months after therapy, DIB values after laser decontamination and augmentation were significantly more favorable than after conventional decontamination and augmentation. This difference was no longer detectable at the end of the study. **Conclusion:** Based on the results of this study, it may be concluded that the treatment of peri-implantitis may be accelerated by using a CO₂ laser concomitant with soft tissue resection. However, with respect to long-term results in augmented defects, there seems to be no difference between laser and conventional decontamination. *INT J ORAL MAXILLOFAC IMPLANTS* 2007;22:79–86

Key words: CO₂ laser, guided bone regeneration, peri-implantitis

In oral rehabilitation, a continually increasing number of patients are treated with dental implants. As a consequence, an increasing number of peri-implant complications may also be expected over the long term.¹ Treatment of peri-implantitis requires decontamination of the implant surface and augmentation of the defect. Guided bone regeneration (GBR), either alone or in combination with bone grafts, has been used to treat implant surface expo-

sure in dehiscence-type defects² or peri-implantitis defects.^{3–5} However, based on these reports, it appears that actual reosseointegration is difficult or impossible to achieve.⁵

Factors that may influence reosseointegration include the surface texture of the implant, bone defect morphology, bone graft material, membrane exposure, and alteration of the reactive superficial titanium oxide during the decontamination procedure.^{3,5} Additionally, it is known that conventional decontamination with dental curettes and air-powder abrasives does not result in either sterile or isotonic sites.^{6–8} Braß and Anil⁸ reported that narrow bony defects do not allow complete instrumentation of implant surfaces with dental curettes and air-powder abrasives. Furthermore, these methods are not innocuous; in fact, sudden death caused by embolism has been reported following the infracrestal application of air-powder abrasives.⁹

¹Oral Surgeon, Department of Oral and Maxillofacial Surgery, Technical University of Munich, Germany.

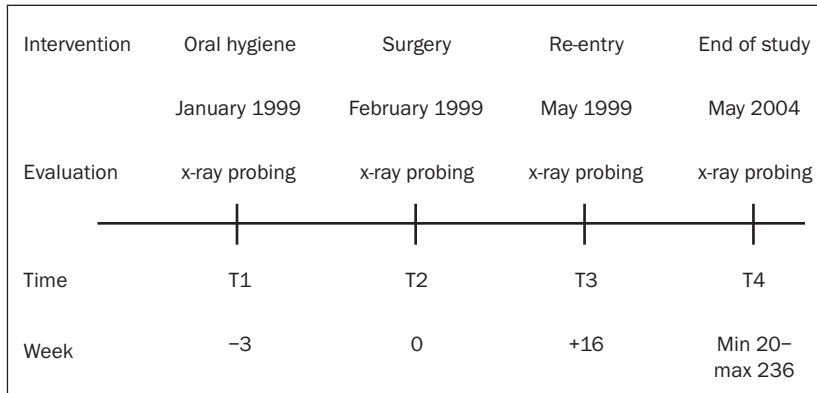
²Oral and Maxillo-Facial Surgeon, Department of Oral and Maxillofacial Surgery, Technical University of Munich, Germany.

Correspondence to: Dr Herbert Deppe, Technical University of Munich, Germany, Klinikum rechts der Isar, Ismaninger Straße 22, 81675 München, Germany. Fax: +089 4140 2934. E-mail: herbert.deppe@mkg.med.tum.de



Fig 1 (Above) Angled mirrors (90 and 120 degrees) mountable to the handpiece of a medical CO₂ laser (DEKA, Freising, Germany).

Fig 2 (Right) Outline of the clinical study.



In the beagle dog model, it has been shown that CO₂-laser-assisted decontamination enables sterilization of exposed implant surfaces and reosseointegration.^{10,11} This was explained by the fact that carbon dioxide laser energy is not absorbed to any significant extent by metallic surfaces, which reduces the potential for damage to the implant and thermal injury to underlying tissues.¹² It has also been shown that carbon dioxide laser irradiation has an important potential for sterilization by virtue of its excellent absorption in water.¹⁰ Accordingly, the CO₂ laser has also been recently recommended for applications in implant dentistry such as uncovering implants at second-stage surgery and decontamination of exposed implant surfaces.¹²

Current literature convincingly indicates that the decontamination method, itself, may exert influence on the results of peri-implantitis treatment. Moreover, the results also seem to depend on the augmentation material used.^{4,13} Recently, it has been shown that synthetic pure-phase beta-tricalcium phosphate may be useful for certain applications in oral surgery,^{14,15} but it is not yet clear if this substance is indicated for the treatment of peri-implant defects. The purpose of this clinical study was to determine whether CO₂ laser-assisted decontamination—with or without the concomitant use of a synthetic pure-phase beta-tricalcium phosphate ceramic—is of value in the treatment of ailing implants in humans.

MATERIALS AND METHODS

Dental Laser

The CO₂ laser employed was the model 20 C manufactured by the DEKA company (Freising, Germany). This laser emits a beam of monochromatic light with a wavelength of 10.6 μm. The 20 C has a power output range from 1 to 20 W and can be operated in

either a continuous, pulsed, or superpulsed mode. In superpulse mode, mean power is generated by increasing the frequency of pulses; the energy of each superpulse is 20 mJ. In this mode, maximum wattage output is limited at 7 W. A handpiece with a focal length of 125 mm was used. When focused, the spot has a diameter of 200 μm.¹⁰ Angled mirrors can be mounted on the handpiece, thereby allowing the laser beam to reach distant implant surfaces (Fig 1).

In addition the Swiftlase scanner (DEKA) was used to reduce local heat accumulation by sweeping a focused CO₂ laser beam in 0.1 second over an area with a diameter of 3.0 mm (resulting in a total of 7.06 mm²). As a result, the dwell time on each individual point of this area was less than 1 millisecond.¹⁰

Patients

The study sample included 32 patients with 73 ailing implants (defined as “ailing” because of the presence of progressive vertical bone loss, probing depth ≥ 5 mm, or bleeding on probing). Presurgical treatment consisted of chlorhexidine application (0.3%) for 3 weeks (T1 = beginning of hygiene phase, Fig 2). Antibiotics were not administered at any time before or after surgery.

All patients were informed about the therapeutic options available. Augmentation was only recommended for patients with screw-retained prostheses. In these cases, a submerged healing time of 4 months was allowed before the implants were reloaded. If restorations were cemented, soft tissue resection was recommended following decontamination. In those cases, reloading was performed immediately after the decontamination procedure.

There were 8 patients with edentulous mandibles who had been treated with implant-supported overdenture (32 implants), 21 patients with screw-retained prostheses (38 implants), and 3 patients with single-tooth restorations (3 implants). Conventional decontamination plus soft tissue resection was

performed in 6 patients with 19 implants (group 1; 17 IMZ and 2 Frialit-2; Friadent, Mannheim, Germany). Conventional decontamination and bone augmentation was performed in 7 patients with 15 implants (group 2; 8 IMZ, 5-Frialit-2, and 2 Brånemark System; Nobel Biocare, Göteborg, Sweden). Laser decontamination plus soft tissue resection was performed in 10 patients with 22 implants (group 3; 13 IMZ, 4 Frialit-2, 2 Brånemark, and 3 Straumann screw-type; Straumann, Basel, Switzerland). Laser decontamination and bone augmentation was performed in 9 patients with 17 implants (group 4; 11 IMZ, 3 Frialit-2, 2 Brånemark, and 1 Straumann screw-type) (Table 1).

Treatment Protocol

Immediately prior to surgery, all screw-retained prostheses were removed; cemented restorations were left in situ. After raising full-thickness flaps, surgical treatment consisted of granulation tissue removal and implant decontamination (T2 = surgical intervention). All 73 implant surfaces were cleaned initially with an air-powder abrasive (Prophy-Jet; Dentsply, York, PA) for 60 seconds, but only at the supracrestal aspect to avoid embolization.

In groups 3 and 4 (22 and 17 implants, respectively), all implant surfaces were additionally subjected to CO₂ laser irradiation. According to the results of a previous study, superpulse irradiation can have adverse effects on the surface properties of lased implants.¹¹ Therefore, continuous wave mode (cw) irradiation was used throughout the study with the parameters specified previously (cw 2.5 W, 12 × 5 seconds).¹⁰ Throughout the study, the Swiftlase scanner was used. In cw mode, an energy density (ie, a fluence) of 175 Jcm⁻² resulted from an exposure time of 5 seconds.

The tiny CO₂ laser beam also enabled decontamination at the infracrestal aspects of the implants without the risk of embolization. However, because of the architecture of the defects, perpendicular laser beam delivery was not possible in all cases. If perpendicular laser beam delivery was not possible, the circular form of irradiation provided by the scanner resulted in a more oval-shaped geometry.

Following the decontamination procedure, for a total of 41 implants, soft tissue resection was performed (19 implants after conventional decontamination, 22 implants after laser irradiation) (Table 1). Augmentation was performed for 32 implants (15 implants after conventional decontamination, 17 after laser irradiation). For this purpose, a resorbable beta-tricalcium phosphate (βTCP or Cerasorb; Curasan, Kleinostheim, Germany) was used in combination with bone harvested from the retromolar region of the mandible (50:50 ratio). The implants

Table 1 No. of Implants at Various Evaluation Points

	Group 1	Group 2	Group 3	Group 4
T1	19	15	22	17
T2	19	15	22	17
T3	15	11	20	17
T4	16	11	17	13
Lost implants	3	4	2	4

Group 1 = conventional decontamination, implants placed in residual bone; group 2 = conventional decontamination, implants placed in augmented bone; group 3 = laser decontamination, implants placed in residual bone; group 4 = laser decontamination, implants placed in augmented bone.

"Lost implants" indicates the number of implants lost because of the progression of peri-implantitis. Differences between T1 and T4 are attributable to the numbers of lost implants and to the fact that not all patients provided consent for the recall evaluation.

were submerged and covered by nonresorbable membranes (Gore-Tex G 4; W. L. Gore & Associates, Flagstaff, AZ). For 2 implants, following laser irradiation, the membranes were draped without the concomitant use of βTCP. After the decontamination and augmentation procedures, the full-thickness flaps were carefully resected, redraped, and sutured (Figs 3a to 3d).

Data Collection

Clinical evaluation of the peri-implant tissues was carried out at the beginning of the hygiene phase (T1, ie, 3 weeks before surgery), immediately prior to surgery (T2), 4 months after therapy (T3), and in May 2004 (T4). The peri-implant parameters were assessed according to the criteria proposed by Buser and colleagues¹⁶ and Mombelli and associates¹⁷ on all 4 sites (mesial, distal, lingual, and buccal) and included plaque index (PI), sulcus bleeding index (SBI), probing depth (PD), distance implant-mucosa (DIM) and clinical attachment level (AL). Measurements were made from the implant shoulder with a periodontal probe PCP 11 (Aesculap, Tuttlingen, Germany; Table 2). Assessment of PI and SBI allowed observation of oral hygiene over the 5-year period. If PI and SBI were indicative of poor oral hygiene, resection and reinstruction were performed.

In augmented implant sites without dehiscence, clinical parameters were recorded 2 weeks after the membranes were removed (ie, T3 + 2 weeks). If dehiscence occurred, the membranes were removed immediately; evaluation, however, was performed regularly at T3.

Radiographs were not obtained routinely for all patients, since many refused consent. Consequently, standardized evaluation of the peri-implant bone level with the calculation of mean annual bone gain

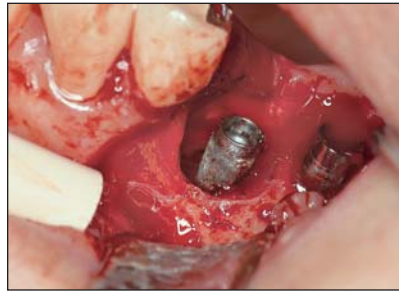
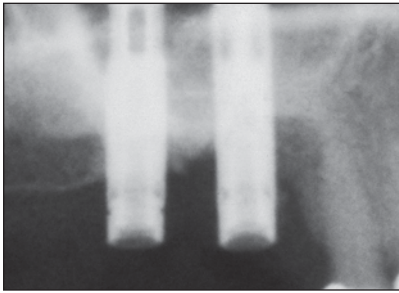


Fig 3a (left) Radiograph indicating chronically progressive peri-implant bone resorption.

Fig 3b (right) Surgical intervention: full-thickness flap elevation and granulation tissue removal.

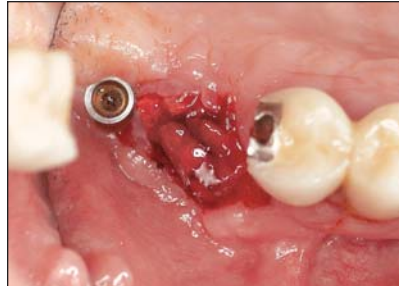
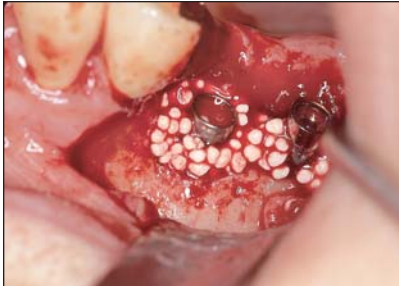

Fig 3c (left) CO₂ laser-assisted implant decontamination and augmentation with βTCP and autogenous bone (50:50 ratio).

Fig 3d (right) Re-entry 4 months after therapy immediately after membrane removal.

Table 2 Clinical Evaluation Results

Group/time	PI	SBI	PD	DIM	AL	DIB
1						
T1 (n = 19)	1.8 ± 1.2	2.7 ± 0.9	6.2 ± 1.8	1.1 ± 1.2	7.3 ± 1.3	7.8 ± 1.6
T2 (n = 19)	0.7 ± 0.8	0.7 ± 0.8	5.1 ± 1.3	1.9 ± 1.1	7.0 ± 0.9	7.6 ± 1.4
T3 (n = 15)	0.6 ± 0.7	0.9 ± 0.5	3.2 ± 0.9	3.1 ± 1.4	6.3 ± 1.1	7.2 ± 1.9
T4 (n = 16)	0.8 ± 0.8	1.1 ± 1.2	4.3 ± 1.2	2.7 ± 1.4	7.0 ± 0.9	7.9 ± 1.3
2						
T1 (n = 15)	1.4 ± 1.2	2.3 ± 1.4	5.1 ± 1.7	1.7 ± 1.4	6.8 ± 1.2	7.4 ± 1.1
T2 (n = 15)	0.9 ± 0.4	0.5 ± 0.8	4.8 ± 1.4	1.1 ± 1.5	5.9 ± 1.1	6.8 ± 1.2
T3 (n = 11)	0.6 ± 0.6	0.6 ± 0.6	2.4 ± 0.7	1.1 ± 1.2	3.5 ± 1.2	4.1 ± 0.9
T4 (n = 11)	1.1 ± 0.8	2.1 ± 1.4	2.5 ± 1.1	1.3 ± 1.4	3.8 ± 0.5	4.7 ± 1.1
3						
T1 (n = 22)	1.4 ± 0.9	2.8 ± 1.2	5.7 ± 1.4	1.5 ± 1.8	7.2 ± 1.5	7.4 ± 1.1
T2 (n = 22)	0.7 ± 0.8	0.6 ± 0.3	6.1 ± 1.6	0.8 ± 1.2	6.9 ± 0.8	7.2 ± 1.3
T3 (n = 20)	0.8 ± 0.6	0.7 ± 0.6	2.1 ± 1.3	3.4 ± 0.8	5.5 ± 0.9	6.9 ± 1.4
T4 (n = 17)	1.0 ± 1.3	1.8 ± 1.1	3.4 ± 1.5	3.2 ± 1.4	6.6 ± 0.7	6.8 ± 0.9
4						
T1 (n = 17)	2.6 ± 0.5	3.3 ± 0.6	5.7 ± 1.4	1.5 ± 1.3	7.2 ± 1.1	7.6 ± 1.1
T2 (n = 17)	0.5 ± 0.6	1.2 ± 0.6	5.0 ± 1.3	1.3 ± 1.4	6.3 ± 1.3	6.7 ± 1.5
T3 (n = 17)	0.5 ± 0.4	0.9 ± 0.8	1.0 ± 0.7	0.6 ± 0.8	1.6 ± 1.5	2.3 ± 0.9
T4 (n = 13)	1.2 ± 1.3	1.9 ± 1.0	2.5 ± 1.4	1.1 ± 1.5	3.6 ± 1.4	4.5 ± 1.2

Means ± SDs shown. Group 1 = conventional decontamination, implants placed in residual bone; group 2 = conventional decontamination, implants placed in augmented bone; group 3 = laser decontamination, implants placed in residual bone; group 4 = laser decontamination, implants placed in augmented bone. T1 = beginning of hygiene phase, T2 = surgical intervention, T3 = 4 months after therapy, T4 = May 2004. DIB = distance from implant shoulder to first bone contact.

or loss was precluded. However, to monitor the progress of healing, standardized orthopantomograms were taken at each examination from T1 to T4 if consent was given. The distance from the implant shoulder to the first bone contact (DIB) was calcu-

lated at mesial and distal sites on the radiographs according to the method of Buser and colleagues.¹⁶ The implant features, with design characteristics of known size, facilitated radiographic measurements of crestal bone level at the approximal sites.

Table 3 Analysis of Clinical Attachment Levels

	Mean \pm SD	n	t	Statistically significant difference?
T3 (Residual bone)				
Group 3	5.5 \pm 0.9	20	-3.87	Yes
Group 1	6.3 \pm 1.1	15		
T3 (Augmented bone)				
Group 4	1.6 \pm 1.5	17	-5.06	Yes
Group 2	3.5 \pm 1.2	11		
T4 (Residual bone)				
Group 3	6.6 \pm 0.7	17	-2.28	Yes
Group 1	7.0 \pm 0.9	16		
T4 (Augmented bone)				
Group 4	3.6 \pm 1.4	13	-0.48	No
Group 2	3.8 \pm 0.5	11		

Table 4 Analysis of Radiographic DIB Values

	Mean \pm SD	n	t	Statistically significant difference?
T3 (Residual bone)				
Group 3	6.9 \pm 1.4	20	-0.91	No
Group 1	7.2 \pm 1.9	15		
T3 (Augmented bone)				
Group 4	2.3 \pm 0.9	17	-8	Yes
Group 2	4.1 \pm 0.9	11		
T4 (Residual bone)				
Group 3	6.8 \pm 0.9	17	-4.8	Yes
Group 1	7.9 \pm 1.3	16		
T4 (Augmented bone)				
Group 4	4.5 \pm 1.2	13	0.55	No
Group 2	4.7 \pm 1.1	11		

Statistical Analysis

Statistical analysis was performed using a commercial computer program (MS Excel, Microsoft, Redmond, WA). Data are presented as means \pm standard deviation or as counts or proportions (Tables 3 and 4).

Two-tailed Student *t* tests permitted comparison of the clinical and radiologic parameters in the 4 treatment groups. *P* \leq .05 in the 2-tailed test was considered to indicate statistical significance.

RESULTS

Table 1 provides information on the numbers of implants that were evaluated at T1 to T4. The number of lost implants is also shown. Differences between T3 and T4 are attributable to the fact that not all patients consented to the repeat evaluation. Mean duration of follow-up in May 2004 was 37 months (5 months minimum, 59 months maximum, ie, 20 – 236 weeks; Fig 2).

Clinical Observations

With the exception of typical postoperative edema, most of the treated defect sites healed uneventfully (Figs 3d, 4a, and 4b). However, in 1 patient in group 2, after conventional decontamination plus augmentation, a severe infection developed, resulting in total loss of the augmentation and all 4 implants within the first weeks after surgery. In a patient in group 4, most of the augmentation and all 4 implants were lost about 10 months after treatment because of a chronic infection.

Clinical Parameters

Table 2 provides information on the clinical parameters in groups 1 through 4, including PI, SBI, PD, and AL. With respect to PI and SBI, all groups demonstrated very similar values: At T1 (the beginning of the hygiene phase), the highest values were observed. Subsequently, PI and SBI each dropped about 2 index points at the time of surgery (T2) but increased further into the investigation (T3 or T4).

AL in the 4 groups showed clearly different responses. Initially, at times T1 and T2, there were no

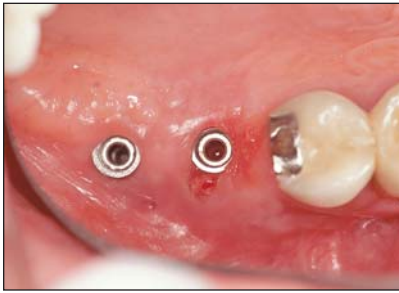

Fig 4a (left) Clinical result 27 months after surgery.

Fig 4b (right) Radiographic result 27 months after surgery.

statistically significant differences between the groups. However, because of the soft tissue resection in groups 1 and 3, the AL values were substantially higher in these groups than in groups 2 and 4, which were treated with augmentation. At T3 and T4, there was a statistically significant difference between groups 1 and 3 as well ($P \leq .05$) (Tables 2 and 3). In groups 2 and 4, however, statistically significant differences were found at the .05 level at T3 but not at T4 (Tables 2 and 3).

Radiology

Table 2 provides data on the bony attachment (DIB values) from T1 to T4. While there were no statistically significant differences between the 4 groups at times T1 and T2, this was not the case at T3 and T4. Because of the soft tissue resection in groups 1 and 3, the DIB values were higher in these groups than in groups 2 and 4, which were treated with augmentation. There was no statistically significant difference at T3 between groups 1 (conventional decontamination plus soft tissue resection) and 3 (laser decontamination plus soft tissue resection). However, at T4, group 3 was found to have significantly smaller DIB values ($P \leq .05$) than those seen with conventional therapy (group 1; Tables 2 and 4). In groups 2 and 4, however, statistically significant different DIB values were found at the 0.05 level at T3 but not at T4 (Tables 2 and 4).

DISCUSSION

It was recently proposed that reosseointegration of ailing implants is not feasible because technical problems preclude complete decontamination of the exposed implant.^{3,5} However, it has been shown in vitro and in vivo that various laser wavelengths may have the potential to impede the progression of bone resorption caused by peri-implant infections.^{10,18–21} For this purpose, several authors have recommended the use of diode lasers ($\lambda = 810$ nm and 906 nm)^{18,19} and Er-YAG lasers ($\lambda = 2.94$ μm).²⁰ Histologic studies in the beagle dog have shown that

CO₂ laser-assisted implant decontamination can resolve technical problems associated with decontamination, especially in narrow defects.^{10,11} Consequently, the purpose of this study was to assess the efficacy of CO₂ laser-assisted versus conventional implant decontamination used in combination with a resorbable augmentation material in humans.

For the treatment of peri-implant infections, most authors recommend antibiotic therapy, implant decontamination with air-powder abrasives, and, if possible, augmentation of the defects.^{3,4,8,10,13,21} To date, there is little evidence to support antibiotic therapy. Mombelli and coworkers¹⁷ demonstrated that systemic application of Ornidazol (2×500 mg per 10 days) resulted in a less pathogenic peri-implant flora. Systemic application of antibiotics always carries the risk of adverse effects and can promote the emergence of microbial resistance. Even the most effective antibiotics are not suitable for detoxification of the implant surface, which seems to be necessary for reosseointegration. Consequently, Braß and coworkers recommended the use of hand curettes and air-powder abrasives.⁸ Results from this study at 3 months showed that probing depth was reduced about 0.9 mm and that the attachment level was also improved approximately 0.9 mm: findings similar to those were seen in groups 1 and 3 of the present study (Table 2). However, the authors concluded that decontamination and detoxification of implant surfaces cannot be achieved using hand curettes in narrow bony defects.⁸ Infracrestal application of air-powder abrasives may cause embolization⁹; laser application, however, is not associated with such serious risks.

There are several reports in the literature in which laser decontamination has been recommended. Application of a diode laser ($\lambda = 810$ nm) resulted in recurrence rates of less than 7%.¹⁸ In the present study, laser-assisted implant decontamination plus soft tissue resection (group 3) resulted in significantly more favorable levels of clinical attachment than conventional decontamination plus soft tissue resection at T3 as well as T4 (Table 3). It may be assumed that the CO₂ laser led to a sufficient reduc-

tion of microorganisms followed by rapid healing of the peri-implant mucosa, indicated by the smaller PD values at T3 (Table 2). In addition, this treatment seemed to improve AL more effectively than the conventional decontamination during long-term follow-up. This is indicated by the significantly better AL values at T4 (Table 3) and the more favorable difference in AL between T1 and T4 in group 3.

When available, the radiographically assessed bone level changes observed in this study indicated that early after treatment (T3), laser-assisted decontamination plus soft tissue resection resulted in bony attachment levels very similar to those yielded by conventional decontamination plus soft tissue resection (DIBs of 6.9 ± 1.4 for laser decontamination versus 7.2 ± 1.9 for the conventional method). This result was not surprising, since laser decontamination is unlikely to promote significant vertical bone gain following soft tissue resection. In contrast, during long-term follow-up (T4), ongoing bone resorption was observed in the conventionally decontaminated group 1 but not following laser decontamination in group 3 (Table 2).

Complete regeneration of peri-implant defects can only be established with the use of augmentation materials following implant decontamination. However, it is not yet clear whether autogenous bone or synthetic materials such as β TCP are of more value for this purpose. Behneke and coworkers¹³ showed in a study of 25 Straumann implants afflicted by severe peri-implantitis that detoxification with air-powder abrasives and use of autogenous bone is suitable for augmentation of peri-implant defects. One year after treatment, radiologic studies showed that the depth of defects had been reduced by about 53%, a finding in accordance with those of the present study at time T3. At T4, however, DIB values in the present study indicated a lesser reduction of the defect depth (about 30% to 40%). Thus, it appears that autogenous bone can lead to more favorable augmentation of peri-implant defects than synthetic materials over the long term.

In another study, Haas and coworkers also reported on augmentation of peri-implant defects with intraorally harvested autogenous bone.²¹ However, decontamination was performed using photodynamic therapy with toluidine blue plus diode laser light ($\lambda = 906$ nm) in 24 ailing implants. This method resulted in a mean bony reapposition of 2 mm (± 1.90 mm) after a 9.5-month observation period. In the present study, CO₂ laser-assisted implant decontamination plus augmentation with resorbable β TCP plus autogenous bone (group 4) resulted in very similar mean bone reapposition during long-term follow-up, ie, T4.

From these results it may be concluded that both autogenous bone and resorbable synthetic materials are suitable for augmentation of peri-implant defects. Observations from the present investigation indicate that the bactericidal effects of laser irradiation are not superior to those of conventional decontamination when combined with augmentation over the long term; laser irradiation cannot prevent reinfection during long-term follow-up. Moreover, the architecture of a defect can prevent perpendicular laser beam delivery and require a variation of the focal length of the handpiece. It is known from the literature that CO₂ laser sterilization can be achieved with a perpendicular fluence of at least 159 Jcm^{-2} .²² However, if the defect form requires inclination of the handpiece by more than 26 degrees from the perpendicular direction to the implant axis, a lethal amount of energy density may not be applied to the implant surface.

Another factor that may have had adverse effects on the sterilization potential of the laser energy is bleeding. Bleeding at the site could have absorbed much of the laser energy, and the depth of the defect may have not allowed the laser energy to reach the surface to be treated. Accordingly, under clinical conditions, there may be some uncertainty regarding whether the laser energy applied is consistently sufficient and whether an equal dose is applied in all cases.

In spite of the different methods used for decontamination and the different materials used for augmentation, comparison of the present results with those found in the literature show roughly comparable amounts of bone gain; ie, 50% of the previous defect depth.^{21,23} Consequently, with respect to the long-term results of augmentation procedures, the method used for decontamination seems to play a subordinate role. Oral hygiene parameters are in support of this conclusion, because in all 4 groups PI and SBI each dropped about 2 index points at the time of surgery (T2) but increased further into the investigation (T3, T4).

CONCLUSION

These results suggest that CO₂ laser decontamination may be more efficacious than conventional decontamination in deep, narrow bony defects and especially when combined with soft tissue resection. Over a 5-year period, clinical and radiographic parameters indicated that decontamination by means of a CO₂ laser could stop the progression of inflammatory bone resorption effectively when combined with soft tissue resection. Augmentation with a 50:50

mix of β TCP and autogenous bone can lead to reduction of the defect depth comparable to that achieved with autogenous bone. However, DIB values in augmented defects following CO₂ laser decontamination were not significantly better than those seen after conventional decontamination during the 5-year follow-up. Consequently, with respect to the results of augmentation procedures, the method used for decontamination seems to play a subordinate role. Further studies are necessary to identify a gold standard for the treatment of ailing implants.

ACKNOWLEDGMENTS

This research project was supported by the Friadent, Mannheim, Germany. The authors wish to thank Prof Dr oec publ Stefan Wagenpfeil, Department of Statistics in Medicine, Technical University of Munich, for his statistical work.

REFERENCES

1. Buchter A, Kleinheinz J, Meyer U, Joos U. Treatment of severe peri-implant bone loss using autogenous bone and a bioabsorbable polymer that delivered doxycycline (Atridox). *Br J Oral Maxillofac Surg* 2004;42:454–456.
2. Jovanovic SA, Spiekermann H, Richter EJ. Bone regeneration around titanium dental implants in dehiscence defect sites: A clinical study. *Int J Oral Maxillofac Implants* 1992;2:233–245.
3. Nociti FH Jr, Caffesse RG, Sallum EA, Machado MA, Stefani CM, Sallum AW. Evaluation of guided bone regeneration and/or bone grafts in the treatment of ligature-induced peri-implantitis defects: A morphometric study in dogs. *J Oral Implantol* 2000;26:244–249.
4. Casati MZ, Sallum EA, Nociti FH Jr, Caffesse RG, Sallum AW. Enamel matrix derivate and bone healing after guided bone regeneration in dehiscence-type defects around implants. A histomorphometric study in dogs. *J Periodontol* 2002;73:789–796.
5. Wetzell AC, Vlassis J, Caffesse RG, Hämmerle CHF, Lang NP. Attempts to obtain re-osseointegration following experimental peri-implantitis in dogs. *Clin Oral Implants Res* 1999;10:111–119.
6. Zablotsky MH, Diedrich DL, Meffert RM. Detoxification of endotoxin-contaminated titanium and hydroxyapatite-coated surfaces utilizing various chemotherapeutic and mechanical modalities. *Implant Dent* 1992;1:154–158.
7. Schou S, Berglundh T, Lang NP. Surgical treatment of peri-implantitis. *Int J Oral Maxillofac Implants* 2004;19(suppl): 140–149.
8. Braß M, Anil A. Periimplantäre Therapie mittels subgingivaler Irrigation und intraoperativem Einsatz von Salzstrahlgeräten. *Z Zahnärztl Implantol* 1991;7:239–242.
9. Messier DY. Coroner's report: Circumstances of a death related to implant surgery procedures. *Int J Oral Implantol* 1989;6:50–63.
10. Deppe H, Horch H-H, Henke J, Donath K. Peri-implant care of ailing implants with the carbon dioxide laser. *Int J Oral Maxillofac Implants* 2001;16:659–667.
11. Deppe H, Greim H, Brill T, Wagenpfeil S. Titanium deposition after peri-implant care with the CO₂ laser. *Int J Oral Maxillofac Implants* 2002;11:707–714.
12. Walsh LJ. The current status of laser applications in dentistry. *Aust Dent J* 2003;48:146–155.
13. Behneke A, Behneke N, d'Hoedt B. Treatment of peri-implantitis defects with autogenous bone grafts: Six-month to 3-year results of a prospective study in 17 patients. *Int J Oral Maxillofac Implants* 2000;15:125–138.
14. Velich N, Nemeth Z, Toth C, Szabo G. Long-term results with different bone substitutes used for sinus floor elevation. *J Craniofac Surg* 2004;15:38–41.
15. Foitzik C, Staus H. Le Fort I osteotomy in atrophied maxilla and bone regeneration with pure-phase beta-tricalcium phosphate and PRP. *Implant Dent* 2003;12:132–139.
16. Buser D, Weber H-P, Lang NP. Tissue integration of non-submerged implants. *Clin Oral Implants Res* 1990;1:33–40.
17. Mombelli A, van Oosten MAC, Schuerch E, Lang NP. The microbiota associated with successful or failing implants. *Oral Microbiol Immunol* 1987;2:145–151.
18. Bach G, Neckel C, Mall C, Krekeler G. Conventional versus laser-assisted therapy of peri-implantitis: A five-year comparative study. *Implant Dent* 2000;9:247–251.
19. Romanos GE, Everts H, Nentwig GH. Effects of diode and Nd:YAG laser irradiation on titanium discs: A scanning electron microscope examination. *J Periodontol* 2000;71:810–815.
20. Schwarz F, Rothamel D, Sculean A, Georg T, Scherbaum W, Becker J. Effects of an Er:YAG laser and the Vector ultrasonic system on the biocompatibility of titanium implants in cultures of human osteoblast-like cells. *Clin Oral Implants Res* 2003;14:784–792.
21. Haas R, Baron M, Dortbudak O, Watzek G. Lethal photosensitization, autogenous bone, and e-PTFE membrane for the treatment of peri-implantitis: Preliminary results. *Int J Oral Maxillofac Implants* 2000;15:374–382.
22. Zakariasen KL, Dederich DN, Tulip J. Bactericidal action of carbon dioxide laser radiation in experimental dental root canals. *Can J Microbiol* 1986;32:942–946.
23. Hämmerle CHF, Fourmousis I, Winkler JR, Weigel C, Brägger U, Lang NP. Successful bone fill in late peri-implant defects using guided tissue regeneration. A short communication. *J Periodontol* 1995;66:303–308.