

The CO₂ Laser as an Aid in Direct Pulp Capping

Andreas Moritz, MD, DMD, Ulrich Schoop, MD, Kawe Goharkhay, MD, and Wolfgang Sperr, MD, DMD

Two hundred direct pulp capping procedures were conducted in the present study. One hundred of them were performed with the CO₂ laser, and 100 were conducted conventionally as a control by using a calcium hydroxide preparation. Follow-up examinations were performed after 1 wk and monthly for 12 months after treatment. Thermal tests were used for vitality assessments and laser Doppler flowmetry for direct measurement of pulpal blood. In the group of pulps treated with the CO₂ laser, the last recall examination at 12 months demonstrated that 89 teeth remained vital, corresponding to a success rate of 89%. In the control group, the success rate was considerably lower (68%). Exposure sizes and mean patient age were nearly identical in both groups. The CO₂ laser seems to be a valuable aid in direct pulp capping.

Direct pulp capping is considered a valid treatment method in today's endodontics, because successful capping can preserve tooth vitality in an exposed pulp cavity.

Already in 1765, Pfaff worked on the problem of treating exposed pulp cavities (1). From today's standpoint, direct pulp capping is indicated only when the pulp is exposed during removal of *healthy* dentin, whereas direct capping after removal of carious dentin often fails (1). Schroeder (in 1981) (2) and Kopel (in 1992) (3) stated that direct capping is indicated only in pulps that have not been affected by inflammation a priori.

Calcium hydroxide preparations are normally used as capping material. Several preparations are commercially available (4). Due to superficial necrosis, resulting from the highly alkaline pH of the capping material and the subsequent formation of fiber-rich scar tissue, normal pulp cells are transformed into secondary odontoblasts and secondary dentin is formed (1).

Success rates reported in the literature vary between 44 and 95% and depend on the size of the exposed pulp area, the location of the site to be capped, and the age of the patients. In 592 cases followed-up of a total 1429 cases, Reuver (in 1992) (5) found a success rate of 91% in the group of 10- to 20-yr-old patients, which continuously dropped to 58% in the group of 70- to 80-yr-old patients. In a type of opening that the author described as "punctiform," the success rate ranged ~73%. When an area of 1 to 9 mm² was exposed, it was 61%. A total of 68% of the teeth were

vital at the last recall examination. However, the timing of the last recall examination varied between 4 months and 24 yr in Reuver's (5) study.

In 1979, a long-term study by Marti (6) revealed that successful healing depends on the age of the patients. He found a success rate of 84% in 10- to 25-yr-old patients, which dropped to only 44% in 46- to 70-yr-old patients. This may be due to the fact that the pulps of younger subjects are richer in cells and have a higher ability to regenerate.

In 1979, Honegger et al. (7) reported a success rate of 83% in a total of 110 teeth subjected to recall examinations.

Melcer et al. (8-10) suggested between the years 1985 and 1987 that the CO₂ laser be used for direct pulp capping and stated that advantages would include an improved restoration (scarring) of the dentin tissue through formation of secondary dentin and, above all, sterilization due to the thermal effects of laser treatment. In 1986, Melcer (9) even described successful pulp restoration after direct capping of inflamed pulps with laser irradiation.

Our study deals with CO₂ laser-assisted direct capping of non-inflamed pulps. We used a cold test and laser Doppler flowmetry for vitality assessment. This method is perfectly suitable for measurements of pulpal blood flow as shown by Gazelius et al. in 1986 (11) and Wilder-Smith in 1988 (12).

MATERIALS AND METHODS

All patients were recruited among the patients of our department. They were randomly subdivided into two groups (a laser group and a control group). In all patients, the pulps had been accidentally exposed during (mechanical) cavity preparation by the inadvertent removal of a layer of healthy dentin. The teeth had been vital before treatment and without any symptoms pointing to pulpitis (i.e., treatment by direct pulp capping was indicated).

Our study included a total of 200 patients; they all had given their written consent to take part in our study. In 100 patients, pulp capping treatment was conducted with the CO₂ laser, whereas the remaining 100 patients were treated with a conventional capping technique using Kerr Life dressing, which contains calcium hydroxide.

Mean patient age in the laser group was 33.4 yr, the youngest and the oldest patient being 8 and 74 yr old, respectively. The exposures had a mean diameter of 0.6 mm, the smallest diameter being 0.1 mm and the largest 1.5 mm. In the control group, the mean age was 33.9 yr, the youngest patient being 9 yr old and the oldest patient 68 yr old. The exposures had a mean diameter of 0.6 mm, the smallest diameter being 0.1 mm and the largest diameter

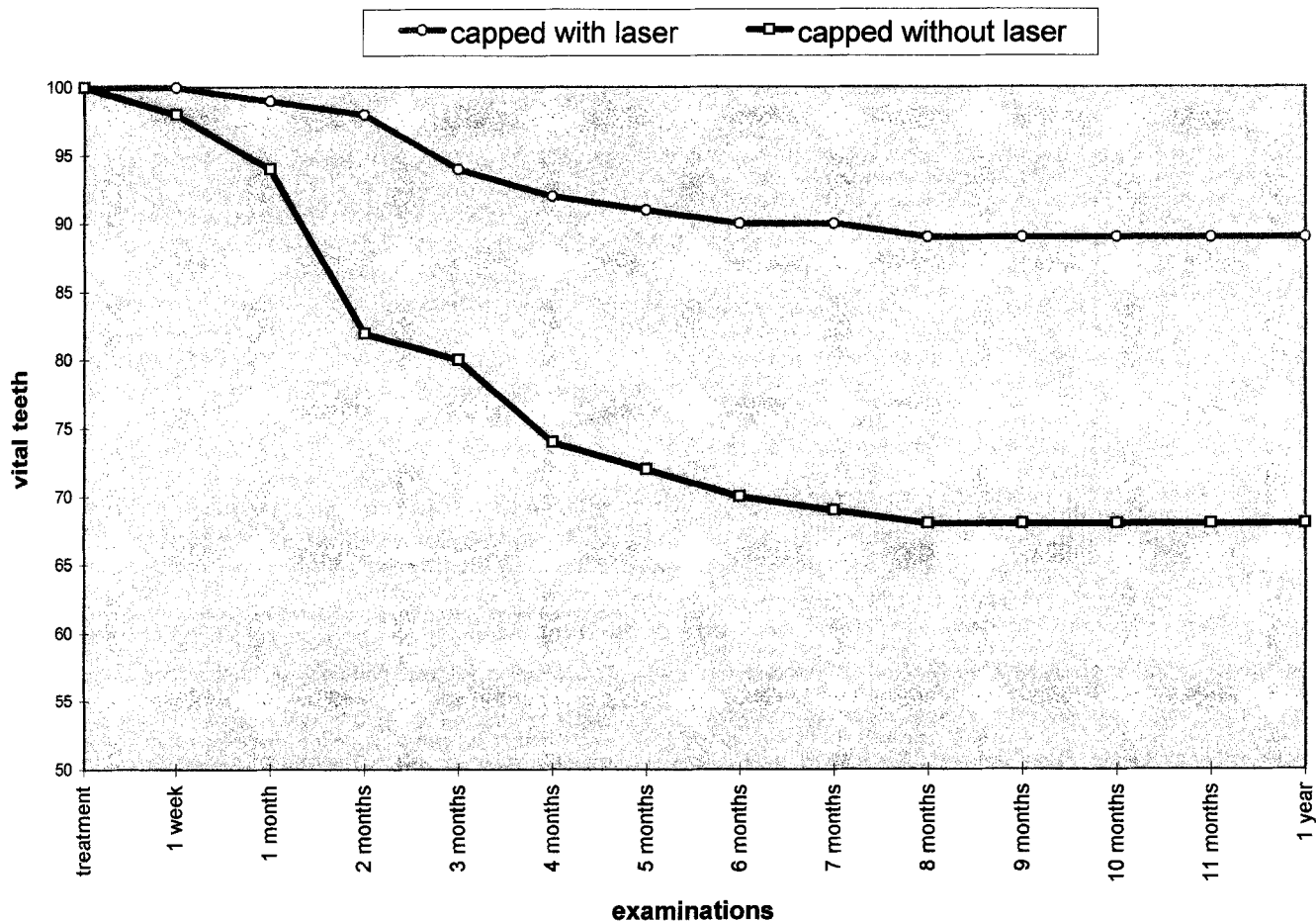


Fig. 1. Percentage of teeth remaining vital at succeeding observation intervals.

1.5 mm. The diameters of the exposures were assessed with the help of a calibrated magnifying glass.

The CO₂ "Lasersat" device by Satelec was used. The wavelength of the emitted infrared radiation ranges $\sim 10.6 \mu\text{m}$. An additional helium-neon aiming beam was incorporated in the delivery system.

In the laser group, we used a laser power output of 1 W to irradiate the exposed pulps. The pulps were irradiated at several intervals; 0.1-s pulses with 1-s pulse intervals. This procedure was repeated until the exposed pulps were completely sealed.

The treated pulps were then dressed with Kerr Life, and the cavities were filled with glass ionomer cement (Ketacfil).

In the control group, the pulps were capped with Kerr Life without prior laser treatment. The cavities were also filled with Ketacfil.

Final filling of the cavities was conducted >6 months.

Recall examinations were conducted after 1 wk and monthly for 1 yr after treatment. We examined the patients' subjective symptoms and the vitality of the treated teeth. To determine tooth vitality, we conducted thermal tests and measurements of pulpal blood flow with laser Doppler flowmetry (using the Periflux 4001 device by Perimed). With this method, typical perfusion curves synchronous with heart beat and vasomotion can be obtained, which allow assessment of the vitality of a tooth. To ensure a reproducible positioning of the laser Doppler probe and to avoid any movement artifacts, we attached the laser Doppler probe to the teeth using silicon impressions.

RESULTS

At the time of the last recall examination at 12 months post-treatment, 89 teeth in the laser group were vital (i.e., they showed a positive reaction to cold and a healthy perfusion index in laser Doppler measurements) and asymptomatic. Only 10 teeth were affected by pulpitis and required extirpation. Thus, the success rate in the laser group was 89%.

The *top curve* in Fig. 1 shows that the number of vital teeth in the laser group dropped only slightly during the recall period. In the control group, only 68 teeth were vital at the last recall examination, corresponding to a success rate of 68%. The *bottom curve* in Fig. 1 shows the vitality development in the control group.

As far as the effects of the size of the exposed pulp region and the mean patient's age on the treatment success are concerned, no significant correlations were found in both groups.

Figures 2 and 3 show the success of treatment in relation to the size of the exposed pulp region and the patients' age, respectively.

All perfusion values obtained in the laser Doppler examination were consistent with the results of the cold test. There were no discrepancies with regard to pulpal blood flow and sensitivity.

DISCUSSION

The present study shows that the CO₂ laser is suitable for direct pulp capping. The success rate of 89% in the laser group is

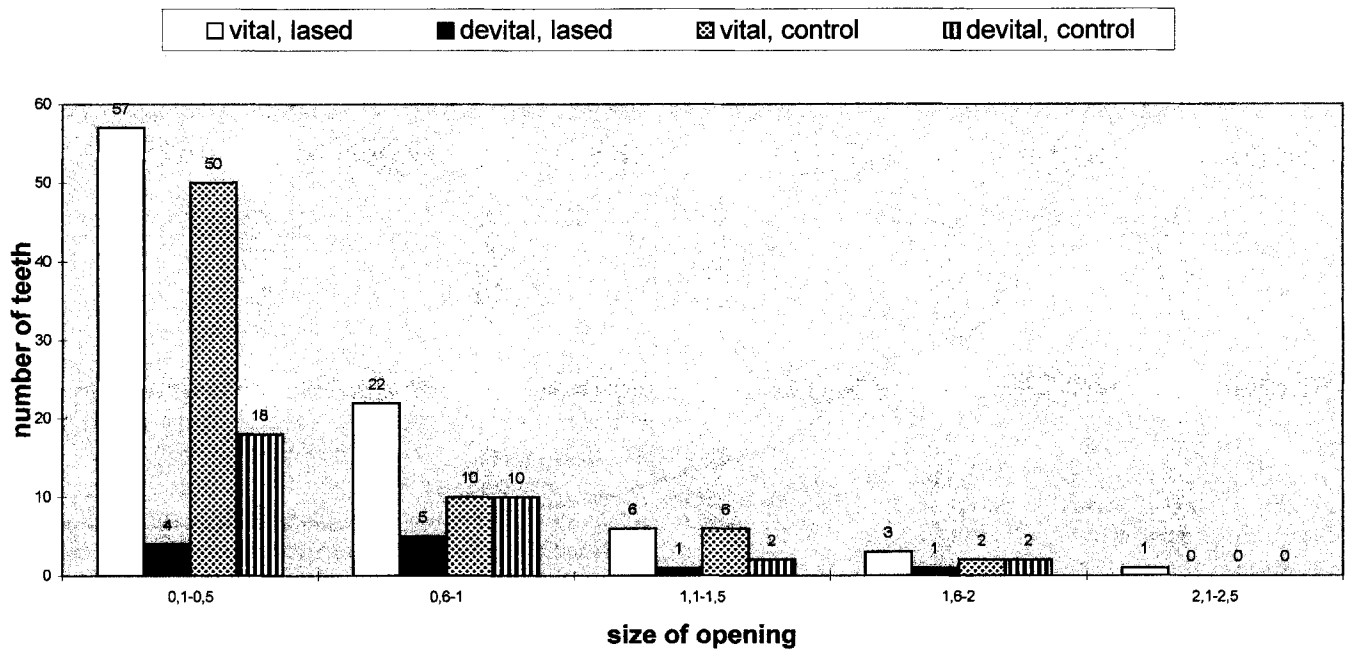


FIG. 2. Tooth vitality (1 yr after treatment) in relation to the size of the opening. All teeth had been vital before treatment.

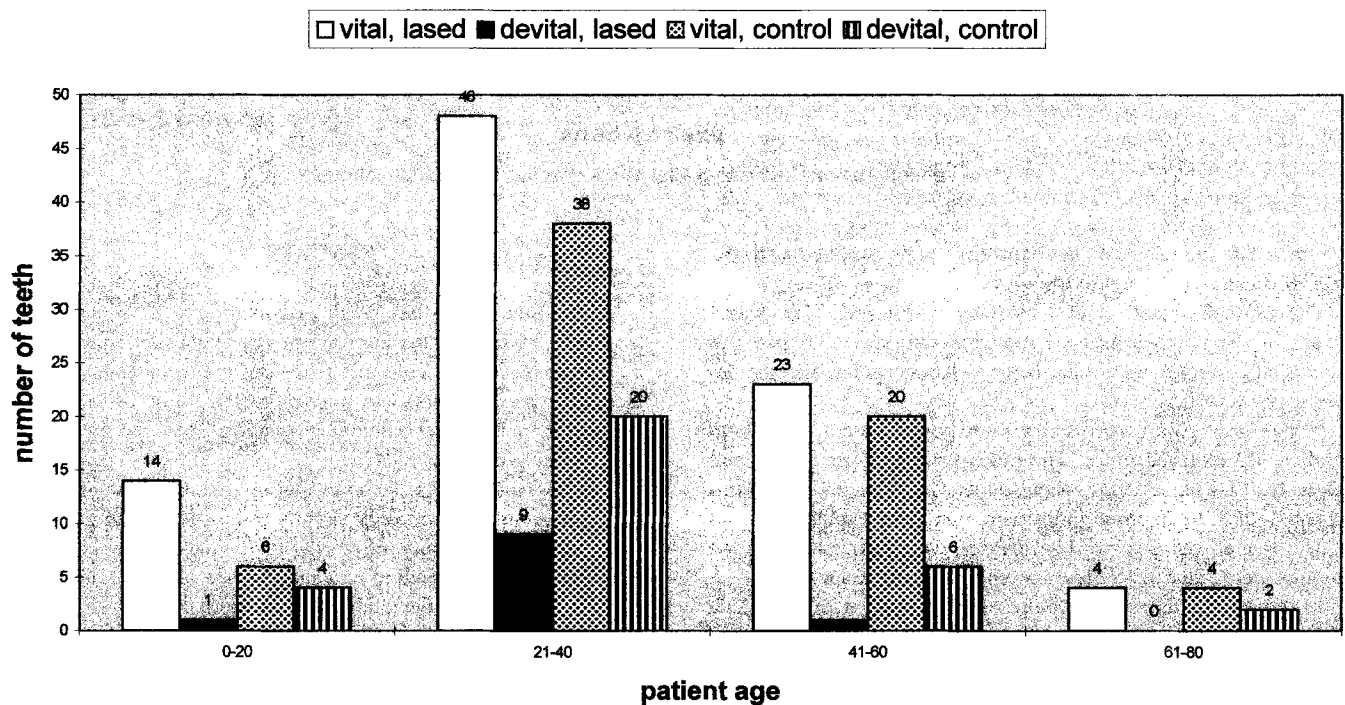


FIG. 3. Tooth vitality (1 yr after treatment) in relation to patient age. All teeth had been vital before treatment.

markedly higher than that obtained in the control group and the success rates reported for conventional pulp capping techniques in the literature. In both groups, the success rate neither depended significantly on the opening's size nor on the mean patient age.

The most important effects of laser irradiation seem to be sterilization and scar formation in the irradiated area due to thermal effects, which may help to preserve the pulp from bacterial invasion. Another effect of laser treatment might be direct stimulation

of dentin formation, as indicated by Paschoud and Holz (13) in 1988. However, unlike us, these authors examined the effects of soft lasers on dentin formation.

The long intervals (1 s) between the pulses (0.1 s), the relatively lower power setting (1 W), and the wavelength (10.6 μm)—which is absorbed within ~100 μm by water—seem to be sufficient to avoid any thermal damage to the pulp. However, using a super-pulsed CO₂ laser instead of the continuous wave, could further

improve the results. This will be the subject of one of our following studies.

In the laser Doppler method, laser light in the infrared range, which is led to the tissue to be examined, undergoes a Doppler frequency shift. A sensor records the wavelength of the light backscattered by moving particles (erythrocytes). By comparing the wavelengths of the light led to the tissue under study and the backscattered light, conclusions can be drawn about blood flow in the capillary region. Because the measurements are not affected by the function of the sensitive pulpal nerve-endings, possible false-negative results of an indirect test can be avoided as shown by Gazelius et al. (11) in 1986.

Vitality control with the laser Doppler technique has been shown to be very reliable, also in luxated and reperfused teeth as shown by Olgart et al. (14) in 1988. In our examinations, the vitality results corresponded exactly to the results of the thermal tests.

We believe that our results give clear proof of the favorable effects of laser application in direct pulp capping and the generally increasing importance of the laser in endodontics.

The authors gratefully thank Professor Dr. Petra Wilder (Smith, Beckman Laser Institute and Medical Clinic, Irvine, CA) for the assistance given to our project.

Drs. Moritz, Schoop, Goharkhay, and Sperr are affiliated with the Department of Conservative Dentistry, School of Dentistry, University of Vienna, Vienna, Austria. Address requests for reprints to Dr. Andreas Moritz, Department of Conservative Dentistry, School of Dentistry, University of Vienna, Waehringerstrasse 25a, A-1090 Vienna, Austria.

References

1. Ketterl W. Endodontie. Zahnerhaltung II, Bd. 3 Praxis d. Zahnheilkunde. Vienna: Urban und Schwarzenberg, 1987:3-81.
2. Schroeder A. Endodontie—Ein Leitfaden für Studium und Praxis. Berlin: Quintessenz, 1981:21-80.
3. Kopel HM. Considerations for the direct pulp capping procedure in primary teeth: a review of literature. ASDC J Dent Child 1992;59:141-9.
4. Foreman PC, Barnes IE. Review of calcium hydroxide. Int Endod J 1990;23:283-97.
5. Reuver J. 592 Pulpaüberkappungen in einer zahnärztlichen Praxis-eine klinische/Prüfung (1966-1990). Dtsch Zahnärztl Z 1992;47:29-32.
6. Marti F. Direkte Pulpaüberkappungen mit Calxyl. Eine Langzeitstudie. Dissertation. Bern, Switzerland: Universität Bern, 1979.
7. Honegger D, Holz J, Baume LJ. Contrôlé clinique a long terme du coiffage pulpaire direct (réalisé par les étudiants de la SMD, Geneve). SSO Schweiz Monatsschr Zahnheilkd 1979;89:1020-41.
8. Melcer J, Chaumette MT, Melcer F. Experimental research on the preparation of dentin-pulp tissue of teeth exposed to CO₂ laser beams in dogs and macaques (*Macaca mulatta* and *Macaca fascicularis*). C R Soc Biol (Paris) 1985;179:577-85.
9. Melcer J. Latest treatment in dentistry by means of the CO₂ laser beam. Lasers Surg Med 1986;6:396-8.
10. Melcer J, Chaumette MT, Melcer F. Dental pulp exposed to the CO₂ laser beam. J Lasers Surg Med 1987;7:347-52.
11. Gazelius B, Olgart L, Edwall L. Non-invasive recording of blood flow in human dental pulp. Endod Dent Traumatol 1986;2:219-21.
12. Wilder-Smith P. A new method for the non-invasive measurement of pulpal blood flow. Int Endod J 1988;21:307-12.
13. Paschoud Y, Holz J. Effect of the soft laser on the neoformation of a dentin bridge following direct pulp capping of human teeth with calcium hydroxide. A histological study with the scanning electron microscope. Schweiz Monatsschr Zahnmed 1988;98:345-56.
14. Olgart L, Gazelius B, Lindh-Strömberg U. Laser Doppler flowmetry in assessing vitality in luxated permanent teeth. Int Endod J 1988;21:1-7.