

Review

The Use of CO₂ Laser in the Treatment of Peri-implantitis

George Romanos,^{1,2} Hua-Hsin Ko,³ Stuart Froum,³ and Dennis Tarnow³

Abstract

Different techniques have been used for the treatment of peri-implant defects. However, there are always questions about the issue of reosseointegration. The present paper explores the recent literature on the topic of peri-implantitis therapy, and presents a surgical protocol for implant surface decontamination using the CO₂ laser, grafting of the defect, and coverage with a membrane according to a clinical case. The results appear to be promising and may improve the long-term clinical outcomes of failing dental implants.

Introduction

ENDOSSEOUS IMPLANTS have a high survival rate in the restoration of fully or partially edentulous patients.¹ However, over a 5-y period, up to 14.4% of dental implants demonstrated peri-implant inflammatory reactions associated with bone loss.²

Implant failure has classically been attributed to bacterial infection, surgical trauma, premature fixture overload, faulty or incorrect prosthetic design, and/or improper surgical placement. The etiology of failure is thought to be infection, if there is bleeding, suppuration, pain, and high plaque and gingival indices (Figs. 1 and 2). This infectious process with progressive bone loss (Fig. 3) seen over time is categorized as peri-implantitis.³

Ideally, bone-to-implant contact should be increased and implants should become reosseointegrated. At present, there is no evidence about the utility of anti-infective treatment to prolong the longevity of an implant. There is also insufficient evidence to support any specific treatment strategy with respect to treatment of peri-implantitis.^{4,5}

Numerous treatments have been recommended for peri-implantitis. Guided bone regeneration (GBR) has been used for the treatment of peri-implant bony defects;^{6–8} however, this procedure has limited efficacy.⁹ Currently, there are no clinical studies or case series documenting successful regenerative procedures in peri-implant bony lesions. Some case series demonstrated limited bone filling after GBR procedures.⁶ To enhance the results, some investigators have suggested that it is necessary to decontaminate defective implant surfaces.^{6,10–13}

Several different methods of implant decontamination have been proposed.¹³ Neither subgingival irrigation with local disinfectants^{12,14,15} nor local antibiotic therapy with tetracycline fibers provided conclusive therapeutic effects.¹⁶ Systemic administration of antibiotics has also been used in the treatment of peri-implantitis; however, the success was limited due to resistant strains of bacteria and ineffective drug dosages.^{17,18} Citric acid application with sandblasting,^{7,19} sandblasting alone,^{20–22} or chlorhexidine irrigation²³ have also been recommended. However, implant decontamination using sandblasting units has been associated with risks such as emphysema.²⁴

In contrast, encouraging results in dogs have been reported using the CO₂ laser for decontamination to improve reosseointegration.²⁵ Findings of this animal study suggested that the laser may be an effective therapeutic modality in the treatment of peri-implantitis.

The purpose of the present paper was to review the literature on the use of the CO₂ laser in the treatment of peri-implantitis, and to discuss the indications, advantages, and disadvantages of this technique.

Materials and Methods

The literature search using MEDLINE at the Waldman Library of the New York University College of Dentistry Kriser Dental Center included a review of 71 articles from peer-reviewed journals published in English from January 1986 to December 2007. The keywords utilized were “carbon dioxide laser” and “implant” (36 articles); “laser” and “peri-implantitis” (23 articles); and “CO₂ laser decontamination” (12

¹Divisions of Periodontology and General Dentistry, Unit of Laser Dentistry, Eastman Dental Center, University of Rochester, Rochester, New York, ²Department of Oral Surgery and Implant Dentistry, Dental School (Carolinum), University of Frankfurt, Frankfurt, Germany, and ³Department of Periodontology and Implant Dentistry, College of Dentistry, New York University, New York, New York.

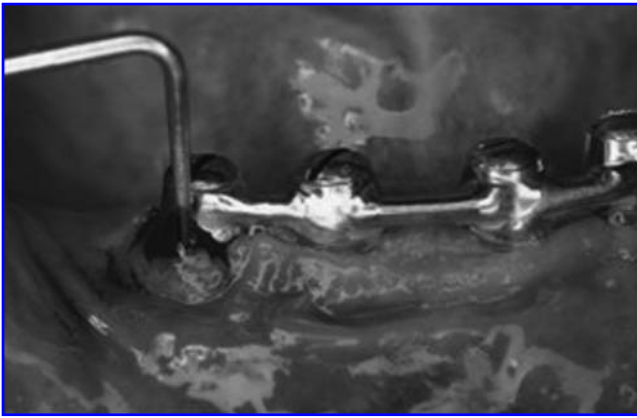

FIG. 1. Deep peri-implant pockets associated with tissue bleeding.

articles). In addition, this paper presents the surgical protocol of the treatment of peri-implantitis using a CO₂ laser according to a clinical case report.

Results

The results of this literature review are presented in Table 1. The data include the type of study, decontamination type, implant surface, augmentation procedure (bone grafting material), and the results. The literature analysis is focused on the use of the CO₂ laser for implant surface decontamination and the treatment of peri-implantitis.

Most of the *in vitro* studies using the CO₂ laser showed no structural changes in the implant surface. In most studies a significant degree of bacterial reduction has been documented. *In vivo* animal studies demonstrated promising results with reosseointegration occurring after CO₂ laser decontamination. In one human clinical study,³⁷ sufficient decontamination led to new bone formation. According to this experience we used a similar protocol to decontaminate the surface of defective implants. After elevation of a mucoperiosteal flap, removal of granulation tissue with plastic curettes, decontamination with a CO₂ laser (Figs. 4, 5, and 6; continuous mode, power levels of 2–4 W, with a non-



FIG. 2. Peri-implant bony defect due to bacteria accumulation (peri-implantitis).

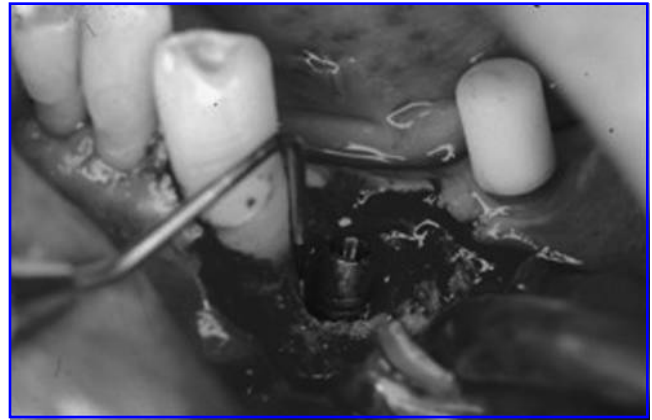


FIG. 3. Measurement of a peri-implant pocket with a periodontal probe (7 mm).

contact defocused handpiece), augmentation with bone grafting material, use of an absorbable membrane (GBR), and flap closure, we found good healing and new bone formation compared to baseline (Fig. 7). Recent clinical studies using the CO₂ laser to decontaminate implant surfaces and bone filling with autogenous bone or bone grafting materials showed good results and long-term success of the oral implants.³⁸

Discussion

Non-surgical methods to treat peri-implantitis include mechanical instrumentation and the use of a variety of antibacterial agents. The antibiotic treatment of peri-implantitis may not allow sufficient bone filling or reosseointegration in deep peri-implant bony defects. Surgical therapy may be necessary to treat peri-implant defects;^{10,11,13} however, to date no treatment method has attained consistent long-term results.

With the protocol described above it is possible to efficiently decontaminate the implant surface and to augment the peri-implant bony defects with either autogenous bone or bone replacement graft materials. In an animal model, osseous filling and reosseointegration were observed. This conclusion was supported by the histological observations by Deppe et al.²⁵ and Stübinger et al.,³⁴ who noted that reosseointegration occurred and bone filling was induced in peri-implant defects after CO₂ laser irradiation.

The physical properties of the laser energy and its interaction with tissues, due to reflection, scattering, transmission, and absorption, may explain why the implant surface can be decontaminated in all areas, including within the threads. The light may induce these antibacterial effects due to its absorption by the implant and the surrounding tissues, or it may be reflected by the metal surface, causing a slight elevation in tissue temperature.

The temperature changes seen during CO₂ laser irradiation have been studied extensively.^{29,39–41} Linear increases to temperatures >50°C were observed with increases in power levels and exposure times, and the pulse mode generated significantly less heat. The results of this study suggest that caution should be exercised when using the CO₂ laser for second-stage dental implant surgery, as the temperatures of

TABLE 1. STUDIES OF CO₂ LASER INTERACTION WITH DENTAL IMPLANTS

Author	Year	Study type	Decontamination technique	Implant surface	Guided bone regeneration	Results
Ganz ²⁶	1994	<i>In vitro</i> study (pig mandibles)	CO ₂	Hydroxyapatite coated		Minimal temperature change
Oyster et al. ²⁷	1995	<i>In vitro</i> study (pig mandibles)	CO ₂			Time and power affected the temperature rise
Kato et al. ²⁸	1998	<i>In vitro</i> study (titanium discs)	CO ₂ CO ₂	Machined, sandblasted		Efficiently decontaminate bacteria without altering implant surface
Mouhyi et al. ²⁹	1999	<i>In vitro</i> study (titanium foil)	CO ₂ + hydrogen peroxide + citric acid	TiO ₂		Re-establishment of the atomic composition and oxide structure
Romanos et al. ³⁰	2001	<i>In vitro</i> (titanium discs)	CO ₂	Various		No surface modifications
Deppe et al. ²⁵	2001	<i>In vivo</i> study (beagle dogs)	CO ₂ , CO ₂ + sandblasting	TPS	e-PTFE only	New bone formation
Romanos et al. ³¹	2002	<i>In vitro</i> (titanium discs)	CO ₂	Sandblasted		Bacterial reduction
Kreisler et al. ³²	2002	<i>In vitro</i> (titanium discs)	CO ₂	Various		No damage
Persson et al. ³³	2004	<i>In vivo</i> study (beagle dogs)	CO ₂ + hydrogen peroxide + systemic antibiotics	Sandblasted large-grit acid-etched, machined	X	New bone formation
Stübinger et al. ³⁴	2005	<i>In vivo</i> study (beagle dogs)	CO ₂	TPS	X	New bone formation
Park et al. ³⁵	2005	<i>In vitro</i> (titanium discs)	CO ₂	Various		No damage
Romanos et al. ³⁶	2006	<i>In vitro</i> (titanium discs)	CO ₂	Various		Osteoblast growth and attachment
Deppe et al. ³⁷	2007	<i>In vivo</i> study (human)	CO ₂	Various	β -TCP + e-PTFE	New bone formation
Romanos and Nentwig ³⁸	2008	<i>In vivo</i> study (human)	CO ₂	Various	Autogenous bone or BioOss + GBR	New bone formation

e-PTFE, expanded polytetrafluoroethylene; β -TCP, β -tricalcium phosphate; TPS, titanium plasma sprayed.




FIG. 4. Handpieces for CO₂ laser irradiation.




FIG. 5. Decontamination of the implant surface and the surrounding tissues with a CO₂ laser (4 W, continuous mode, with a non-contact defocused handpiece).

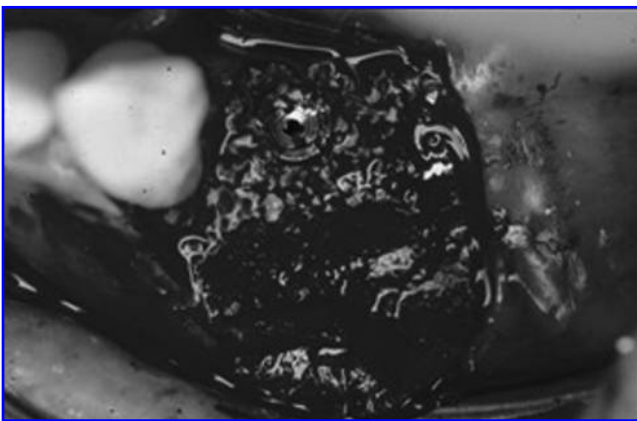


FIG. 6. Augmentation with BioOss® (Shirley, NY).

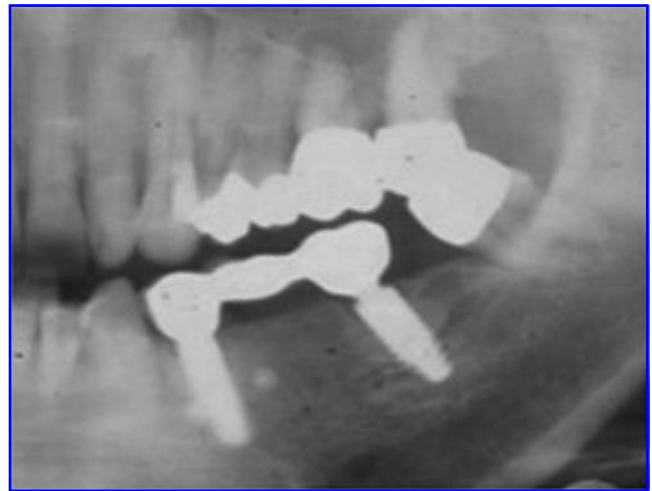

FIG. 7. Radiographic examination 3 y after loading showing excellent formation of new calcified (bone-like) tissue.

dry surfaces exceeded the accepted thresholds for bone damage at clinically relevant settings. However, these temperature changes were measured at the implant-bone interface. Studies have shown that the CO₂ laser produced minimal temperature changes in continuous mode at power levels <4 W, and when used in pulsed mode. Finally, Kreisler et al.⁴¹ concluded that implant surface decontamination with both laser types (CO₂ and GaAlAs) must be time-limited to allow the implant and bone to cool down.

Conclusion

The use of the CO₂ laser in the treatment of peri-implantitis deserves consideration as an efficacious treatment modality, as there appears to be little risk to the patient. However, the surgeon requires special training with respect to safety procedures and laser-tissue interactions. In addition, the cost of the laser unit and its wavelength must also be taken into consideration.

Further clinical and histological research is necessary to determine if long-term success can be achieved, and if reosseointegration affects implant survival and controls the disease process. Special studies using systems with different implant designs and various implant surfaces may be useful to assess the efficacy of this treatment modality.

Disclosure Statement

No conflicting financial interests exist.

References

1. Albrektsson, T., Dahl, E., Enbom, L., et al. (1988). Osseointegrated oral implants—A Swedish multicenter study of 8139 consecutively inserted Nobelpharma implants. *J. Periodontol.* 59, 287–296.
2. Berglundh, T., Persson, L., and Klinge, B. (2002). A systematic review of the incidence of biological and technical complications in implant dentistry reported in prospective longitudinal studies of at least 5 years. *J. Clin. Periodontol.* 29, 197–212.

3. Rosenberg, E.S., Torosian, J.P., and Slots, J. (1991). Microbial differences in 2 clinically distinct types of failures of osseointegrated implants. *Clin. Oral Implants Res.* 2, 135–144.
4. Esposito, M., Hirsch, J., Lekholm, U., and Thomsen, P. (1999). Differential diagnosis and treatment strategies for biologic complications and failing oral implants: a review of the literature. *Int. J. Oral Maxillofac. Implants* 14, 473–490.
5. Klinge, B., Gustafsson, A., and Berglundh, T. (2002). A systematic review of the effect of anti-infective therapy in the treatment of peri-implantitis. *J. Clin. Periodontol.* 29, 213.
6. Grunder, U., Hürzeler, M.B., Schüpbach, P., and Strub, J.R. (1993). Treatment of ligature-induced periimplantitis using guided tissue regeneration: A clinical and histologic study in the beagle dog. *Int. J. Oral Maxillofac. Implants* 8, 282–292.
7. Jovanovic, S. (1993). The management of peri-implant breakdown around functioning osseointegrated dental implants. *J. Periodontol.* 64, 1176–1183.
8. Schüpbach, P., Hürzeler, M., and Grunder, U. (1994). Implant-tissue interfaces following treatment of peri-implantitis using guided tissue regeneration: a light and electron microscopic study. *Clin. Oral Implants Res.* 5, 55–65.
9. Lang, N.P., Mombelli, A., Tonetti, M.S., Brägger, U., and Hämmerle, C. (1997). Clinical trials on therapies for peri-implant infections. *Ann. Periodontol.* 2, 343–356.
10. Lehmann, B., Brägger, U., Hämmerle, C.H.F., Fournousis, I., and Lang, N.P. (1992). Treatment of an early implant failure according to the principles of guided tissue regeneration (GTR). *Clin. Oral Implants Res.* 3, 42–48.
11. Hämmerle, C.H.F., Fournousis, I., Winkler, J.R., Weigel, C., Brägger, U., and Lang, N.P. (1995). Successful bone fill in late peri-implant defects using guided tissue regeneration. A short communication. *J. Periodontol.* 66, 303–308.
12. Zablotsky, M.H. (1993). Chemotherapeutics in implant dentistry. *Implant Dent.* 2, 19–25.
13. Parham, P.L., Cobb, C.M., and French, A. (1989). Effect of an air-powder abrasive system on plasma-sprayed titanium implant surface: an *in vitro* evaluation. *J. Oral Implant.* 15, 78–86.
14. Mombelli, A., and Lang, N.P. (1992). Antimicrobial treatment of peri-implant infections. *Clin. Oral Implants Res.* 3, 162–168.
15. Mombelli, A. (1997). Etiology, diagnosis, and treatment considerations in periimplantitis. *Curr. Opin. Dentistry.* 4, 127–136.
16. Scheck, G., Flemming, T.F., Reuther, J., and Klaiber, B. (1997). Controlled local delivery of tetracycline HCl in the treatment of periimplant mucosal hyperplasia and mucositis. *Clin. Oral Implants Res.* 8, 427–433.
17. Shordone, L., Barone, A., Ramaglia, L., Ciaglia, R.N., and Iacono, V.J. (1995). Antimicrobial susceptibility of periodontopathic bacteria associated with failing implants. *J. Periodontol.* 66, 69–74.
18. Roos-Jansaker, C., Renvert, S., and Egelberg, J. (2003). Treatment of peri-implant infections: a literature review. *J. Clin. Periodontol.* 30, 467–485.
19. Hanisch, O., Tatakis, D.N., Boskovic, M.M., Rohrer, M.D., and Wikesjö, U.M. (1997). Bone formation and reosseointegration in peri-implantitis defects following surgical implantation of rhBMP-2. *Int. J. Oral Maxillofac. Implants* 12, 604–610.
20. Singh, G., O'Neal, R.B., Brennan, W.A., Strong, S.L., Horner, J.A., and Van Dyke, T.E. (1993). Surgical treatment of induced peri-implantitis in the micro pig: Clinical and histological analyses. *J. Periodontol.* 64, 984–989.
21. Hürzeler, M.B., Quinones, C.R., Schupback, P., Morrison, E.C., and Caffesse, R.G. (1997). Treatment of periimplantitis using guided bone regeneration and bone grafts, alone or in combination, in beagle dogs. Part 2: Histologic findings. *Int. J. Oral Maxillofac. Implants* 12, 168–175.
22. Behneke, A., Behneke, N., and d'Hoedt, B. (2000). Treatment of peri-implantitis defects with autogenous bone grafts: Six-month to 3-year results of a prospective study in 17 patients. *Int. J. Oral Maxillofac. Implants* 15, 125–138.
23. Wetzel, A.C., Vlassis, J., Caffesse, R.G., Hammerle, C.H., and Lang, N.P. (1999). Attempts to obtain reosseointegration following experimental peri-implantitis in dogs. *Clin. Oral Implants Res.* 10, 111–119.
24. van de Velde, E., Thielems, P., Schautteet, H., and Vanclooster, R. (1991). Subcutaneous emphysema of the oral flora during cleaning of a bridge fixed on a IMZ implant: Case report. *Rev. Belge. Med. Dent.* 46, 64–71.
25. Deppe, H., Horch, H., Henke, J., and Donath, K. (2001). Peri-implant care of failing implants with the carbon dioxide laser. *Int. J. Oral Maxillofac. Implants* 16, 659–667.
26. Ganz, C.H. (1994). Evaluation of the safety of the carbon dioxide laser used in conjunction with root form implants: A pilot study. *J. Prosthet. Dent.* 71, 27–30.
27. Oyster, D.K., Parker, W.B., and Gher, M.E. (1995). CO₂ lasers and temperature changes of titanium implants. *J. Periodontol.* 66, 1017–1024.
28. Kato, T., Kusakari, H., and Hoshino, E. (1998). Bactericidal efficacy of carbon dioxide laser against bacteria-contaminated titanium implant and subsequent cellular adhesion to irradiated area. *Lasers Surg. Med.* 23, 299–309.
29. Mouhyi, J., Sennerby, L., Nammour, S., Guillaume, P., and Van Reck, J. (1999). Temperature increases during surface decontamination of titanium implants using CO₂ laser. *Clin. Oral Implants Res.* 10, 54–61.
30. Romanos, G.E., Everts, H., and Nentwig, G. (2001). Alterations of the implant surface after CO₂- or Nd:YAG-laser irradiation: A SEM examination. *J. Oral Laser Applic.* 1, 29–33.
31. Romanos, G.E., Purucker, P., Bernimoulin, J., and Nentwig, G. (2002). Bactericidal efficacy of CO₂ laser against bacterially contaminated sandblasted titanium implant. *J. Oral Laser Applic.* 2, 171–174.
32. Kreisler, M., Götz, H., and Duschner, H. (2002). Effect of Nd:YAG, Ho:YAG, Er:YAG, CO₂, and GaAlAs laser irradiation on surface properties of endosseous dental implants. *Int. J. Oral Maxillofac. Implants* 17, 202–211.
33. Persson, L.G., Mouhyi, J., Berglundh, T., Sennerby, L., and Lindhe, J. (2004). Carbon dioxide laser and hydrogen peroxide conditioning in the treatment of periimplantitis: An experimental study in the dog. *Clin Implant Dent. Relat. Res.* 6, 230–238.
34. Stübinger, S., Henke, J., Donath, K., and Deppe, H. (2005). Bone regeneration after peri-implant care with the CO₂ laser: A fluorescence microscopy study. *Int. J. Oral Maxillofac. Implants* 20, 203–210.
35. Park, C.Y., Kim, S.G., Kim, M.D., Eom, T.G., Yoon, J.H., and Ahn, S.G. (2005). Surface properties of endosseous dental implants after Nd:YAG and CO₂ laser treatment at various energies. *J. Oral Maxillofac. Surg.* 63, 1522–1527.
36. Romanos, G.E., Crespi, R., Barone, A., and Covani, U. (2006). Osteoblast attachment on titanium disks after laser irradiation. *Int. J. Oral Maxillofac. Implants* 21, 232–236.

37. Deppe, H., Horch, H., and Neff, A. (2007). Conventional versus CO₂ laser-assisted treatment of periimplant defects with the concomitant use of pure-phase β -tricalcium phosphate: A 5-year clinical report. *J. Periodontol.* 22, 79–86.
38. Romanos, G.E., and Nentwig, G.H. (2008). Regenerative therapy of deep periimplant infrabony defects after CO₂ laser implant surface decontamination. *Int. J. Periodontics Restorative Dent.* 28, 245–255.
39. Swift, J.Q., and Jenny, J.E., and Hargreaves, K.M. (1995). Heat generation in hydroxyapatite-coated implants as a result of CO₂ laser application. *Oral Surg. Oral Med. Oral Pathol. Oral Radiol. Endod.* 79, 410–415.
40. Barak, S., Horowitz, I., Katz, J., and Oelgiesser, D. (1998). Thermal changes in endosseous root-form implants as a result of CO₂ laser application: an *in vitro* and *in vivo* study. *Int. J. Oral Maxillofac. Implants.* 13, 666–671.
41. Kreisler, M., Al Haj, H., Götz, H., Duschner, H., and d'Hoedt, B. (2002). Effect of simulated CO₂ and GaAlAs laser surface decontamination on temperature changes in Ti-plasma sprayed dental implants. *Lasers Surg. Med.* 30, 233–239.

Address reprint requests to:
Dr. Georgios Romanos
Eastman Dental Center
Unit of Laser Dentistry
University of Rochester
625 Elmwood Avenue
Rochester, New York 14620

E-mail: Georgios_Romanos@urmc.rochester.edu